

## The Role of Tomosynthesis and Ultrasound Imaging In Diagnosis of Breast Lesions

Meaad Albashir<sup>1\*</sup>, Mohamed Yousef<sup>2,3</sup>, Naglaa Fawzy<sup>1</sup>, H.Osman<sup>4</sup>

<sup>1</sup>King Abdul Aziz Specialist Hospital (KAASH) Taif, KSA

<sup>2</sup>College of medical radiological science, Sudan university of Science and Technology P O Box 1908, Khartoum, Sudan

<sup>3</sup>Radiologic Science Program, Batterjee Medical College, Jeddah, Saudi Arabia

<sup>4</sup>Taif University College of applied medical science, Radiologic Science Dept, P O Box 2425, Saudi Arabia

### Original Research Article

#### \*Corresponding author

Meaad Albashir

#### Article History

Received: 14.05.2018

Accepted: 22.05.2018

Published: 30.07.2018

#### DOI:

10.21276/sjams.2018.6.7.53



**Abstract:** Breast cancer comprises (10.4%) of all cancer incidences among women, Imaging is most diagnostic tool used to confirm presence of it, in addition to histopathology investigation. This study aimed to assess tomosynthesis and ultrasound in diagnosis the breast lesion. 200 female were investigated, their age 25 years and above in King Abdul Aziz specialist hospital in Taif , Saudi Arabia, among them the most lesion was on the left breast. Ultrasound confirmed 39% were hyperechoic, and 54% (108) were having lesion through tomosynthesis and ultrasound. Ultrasound and tomosynthesis is important diagnostic tool to confirm lesion among breast diseases, through histopathology lesion can be confirmed either malignant or benign. This study recommends the use of imaging and histopathology to confirm lesion.

**Keywords:** Ultrasound, Tomosynthesis, Breast lesion.

### INTRODUCTION

Breast cancer is the most common cause of cancer in women and the second most common cause of cancer death in women in the USA. Breast cancer refers to cancers originating from breast tissue, most commonly from the inner lining of milk ducts or the lobules that supply the ducts with milk[1].

Cancer can be called therefore “Entropic Disease” since it is associated with the increase of entropy of the organism to the point where the organism cannot correct this itself External intervention is required to allow the organism to return to a stable entropic state[2].

There are several types of tumours that may develop within different areas of the breast. Most tumours are the result of benign (non-cancerous) changes within the breast[3]. Cancer develops if the immune system is not working properly and / or the amount of cells produced is too great for the immune system to eliminate [4]. A lack of early detection and access to proper treatment is the cause of greater breast cancer mortality in developing countries[5]. The rate of DNA and RNA mutations can be too high under some conditions such as; unhealthy environment (due to radiation, chemicals, etc.) [3], poor diet (unhealthy cell environment) [6] people with genetic predispositions to mutations [7] and people of advanced age (above 80)[8]. There is strong clinical evidence to support the screening of women for breast cancer despite recent reports to the contrary . The traditional imaging modality for screening has been mammography although more recently other modalities, such as ultrasound and magnetic resonance imaging have been found to serve as useful adjuncts [9].

Worldwide, breast cancer comprises (10.4%) of all cancer incidences among women, making it the second most common type of non-skin cancer (after lung cancer) and the fifth most common cause of cancer death. In 2004, breast cancer caused (519,000) deaths worldwide (7%) of cancer deaths; almost 1% of all deaths). Breast cancer is about 100 times more common in women than in men, although males tend to have poorer outcomes due to delays in diagnosis [1].

Mammography (MG) is the only effective screening method proven to lower mortality in up to 30% (50); it is an accessible, low-cost, low-radiation method. Nonetheless, cancer is not visualized in 10% to 30% of cases. MG is incredibly useful, but not enough for accurate detection. Ultrasound, along with mammography, can increase breast cancer detection rates particularly among high-risk women and in those with denser breasts (60,70). The sensitivity of full-field digital mammography (FFDM) for the detection of breast cancer varies from (75% to 90%), while the

specificity varies from 90% to 95% [10]. One of the shortcomings of traditional X-ray mammography is that it performs poorly when the breasts are dense – often the case for younger women who are less than 50 years of age – and the sensitivity falls to less than 50% [11].

Breast ultrasound is an important modality in breast imaging. It is the usual initial breast imaging modality in those under 30 years of age in many countries. (13. (In assessing for malignancy, is important to remember that one must use most suspicious feature of 3 modalities (pathology, ultrasound, mammography) to guide management [12]. Breast tomosynthesis is a new technology of digital mammography that enables the acquisition of a three-dimensional volume of thin section data, and thus reduces or eliminates tissue overlap (200). Such ability allows visualization of cancers not apparent by conventional mammography (300) and differentiation between benign and malignant lesions (200) [13].

Due to the lack of data and information from our community and local society in Saudi Arabia about breast disorders commonly and breast cancer specifically, also as little of published data worldwide from Arab regions concerning breast cancer, authors considered all these and carried this project to enrich the literature in this field.

The purpose of the current study was to assess the role of 3 dimensional 3D breast tom syntheses in the confirmation/exclusion of breast lesions detected on inconclusive digital mammogram. Since tom synthesis is a multislice modality, authors evaluated its impact on characterization and correlation with ultrasound findings.

## MATERIALS AND METHODS

This is a prospective hospital based study performed in the breast imaging facility at Radiology department during the period from February 2016 to March 2018 at King Abdul-Aziz Specialist Hospital (KAASH), Taif city, Saudi Arabia.

### Study population

A sample comprised of 200 females, their age ranged from 25 years and above living in Taif city have had different types of breast lesions, this sample was collected when the patients attended radiology department for evaluation for their breast masses via mammography screening, gray scale and colour Doppler ultrasound, the results of suspicious masses were confirmed with histopathology, but the last sequence not considered during this manuscript

### Inclusion criteria

Adults Saudi females, ages 25 and above

### Exclusion criteria

Females who were not willing to participate in the study

### Tool of data collection

A structured questionnaire was designed for data collection by the researchers to perform the study based up on review of literature, questionnaire consists from three parts:

#### First part contain

Socio- demographic data (age, marital status and affected side.

#### Second part contain

Ultrasound and Doppler result included information regarding the features of the breast: Shape (Round, Oval or Irregular), Margins (Circumscribed or Ill - defined), Width: AP ratio ( $\leq 1.4$ ,  $\geq 1.4$  or 4 cm) and Echogenicity (Hyperechoic, Hypoechoic or Isoechoic); on the basis of these four features a diagnosis was made. Ultrasound diagnosis was confirmed by FNAC or histopathology to categorize lesions as benign, malignant, or indeterminate.

U/S features that most reliably characterized masses as benign were: a round or oval shape, circumscribed margins, and a width to antero-posterior (AP) dimension ratio greater than 1.4. Features that characterize masses as malignant included irregular shape, microl-lobulations, and width-to-AP dimension ratio of 1.4 or less. A few gently curving, circumscribed lobulations (macro-lobulations) are considered as benign features, whereas many small lobulations of 1-2 mm (micro-lobulation) are considered a malignant characteristic in a recent study.

#### Third part contain

Mammographic and tomosynthesis results

### U/S technique and colour Doppler protocol

Breast U/S requires a high frequency transducer (8-15) MHz. Ideally a wide footprint probe. A lower frequency transducer may be required for the larger attenuated breasts, inflammatory masses and the axilla. The use of a standoff may be required for nipple, superficial/or skin lesions. Low pulse repetition frequency (PRF) colour and spectral Doppler capabilities for assessing vascularity of lesions [6, 5].

### Patient Preparation

Patient will be asked to undress from the waist up and to wear a gown during the examination, lie on his back on the examining table and asked to raise the arm above the head. After he positioned on the examination table, the radiologist (a physician specifically trained to supervise and interpret radiology examinations) or sonographer will apply a warm water-based gel to the area of the body being studied. The gel will help the transducer make secure contact with the

body and eliminate air pockets between the transducer and the skin that can block the sound waves from passing into the body [6].

### **Imaging protocol**

The transducer is placed on the body and moved back and forth over the area of interest until the desired images are captured [6, 7]. There is usually no discomfort from pressure as the transducer is pressed against the area being examined. However, if scanning is performed over an area of tenderness, the patient may feel pressure or minor pain from the transducer. Doppler sonography is performed using the same transducer. Once the imaging is complete, the clear ultrasound gel will be wiped off the skin. Any portions that are not wiped off will dry to a powder. The ultrasound gel does not stain or discolour clothing [6, 6].

### **Ultrasound imaging technique**

She will be lying on her back on the examination bed in the ultrasound room, the upper body undressed, with one arm above your head on the pillow in a comfortable position. The doctor will put a clear gel on your breast and the ultrasound transducer or probe (see ultrasound) will be slowly moved across the breast to show and identify the lesion on the ultrasound screen. The doctor will clean your breast with an antiseptic liquid and place the needle through the skin and into the lesion guided by the ultrasound images. Local anaesthetic on the skin area where the needle is inserted is sometimes given. If the doctor does not provide anaesthetic you can ask about this before the needle is inserted. When the needle is inserted into the lesion, the doctor will make several small (less than 1cm) forward and backward, gentle movements with the needle to collect cells or, if the lesion is a cyst, fluid may be collected. Two or three separate samples are usually taken in this way to ensure a good sample has been obtained [6,8].

Many of the necessary preparations may be before this procedure is no use of aspirin or non-steroidal anti-inflammatory medications (e.g. ibuprofen, naproxen) for one week before the procedure, no food intake a few hours before the procedure, routine blood tests (including clotting profile) must be completed two weeks before the biopsy, suspension of blood anticoagulant medications and antibiotic prophylaxis may be instituted. Before the procedure is started, vital signs (pulse, blood pressure, temperature, etc.) may be taken. Then, depending on the nature of the biopsy, an intravenous line may be placed. Very anxious patients may want to be given sedation through this line. For

patients with less anxiety, oral medication (Valium) can be prescribed to be taken before the procedure [6, 9, 7, 17]

### **Tomosynthesis protocol**

Tomosynthesis is a digital method for performing high-resolution limited-angle tomography at radiographic dose levels. It has been studied for a variety of clinical applications, including vascular imaging, dental imaging, orthopedic imaging, mammographic imaging, musculoskeletal imaging, and chest imaging[7,2].

The concept of tomosynthesis was derived from the work of Ziedses des Plantes, who developed methods of reconstructing an arbitrary number of planes from a set of projections. Though this idea was displaced by the advent of computed tomography, tomosynthesis later gained interest as a low-dose tomographic alternative to CT[7,3].

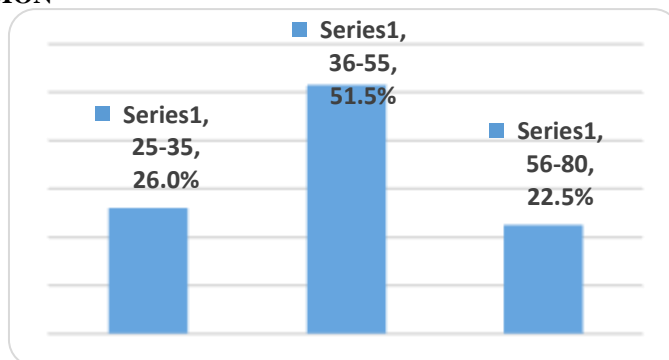
Tomosynthesis reconstruction algorithms are similar to CT reconstructions, in that they are based on performing an inverse Radon transform. Due to partial data sampling with very few projections, approximation algorithms have to be used. Filtered back projection and iterative, expectation-maximization algorithms have both been used to reconstruct the data[7,4].

Reconstruction algorithms for tomosynthesis are different from those of conventional CT because the conventional filtered back projection algorithm requires a complete set of data. Iterative algorithms based upon expectation maximization are most commonly used, but are computationally intensive. Some manufacturers have produced practical systems using off-the-shelf GPUs to perform the reconstruction in a few seconds.

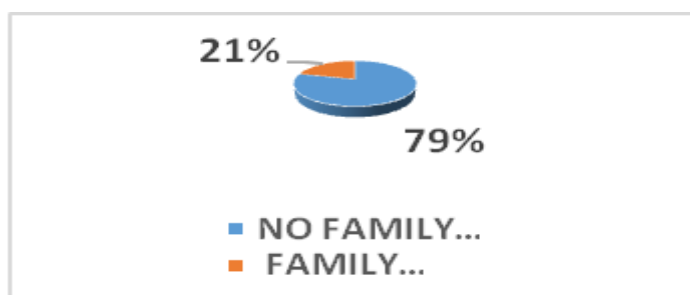
Tomosynthesis is Food and Drug Administration (FDA) approved for use in breast cancer screening[15]. As of 2016 however it is unclear if its use in screening normal risk women is beneficial or harmful[7,6].

Digital breast tomosynthesis (DBT) can provide a higher diagnostic accuracy compared to conventional mammography. In DBT, like conventional mammography, compression is used to improve image quality and decreases radiation dose. The laminographic imaging technique dates to the 1930s and belongs to the category of geometric or linear tomography [17-19].

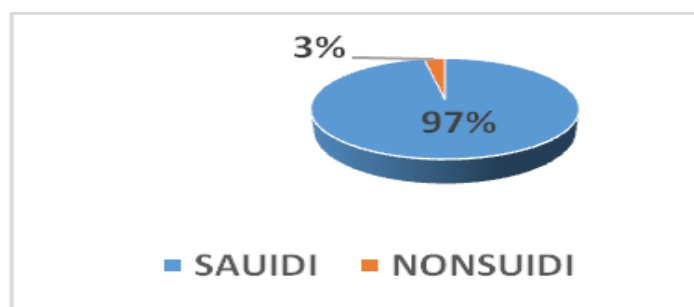
RESULTS AND DISCUSSION



Graph-1: Age distribution among study sample.(n=200)



Graph-2: Family history of breast cancer among study sample.(n=200)



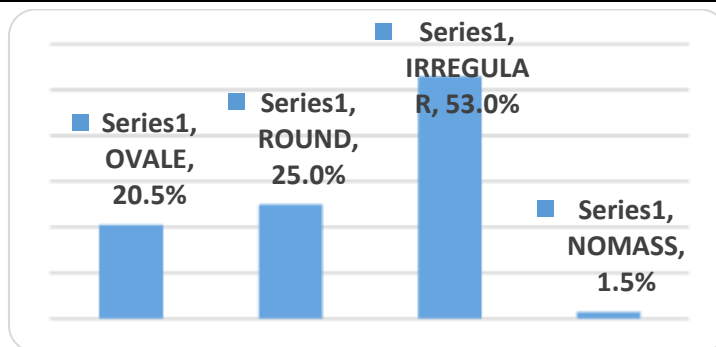
Graph-3: Nationality of patient among study sample (n=200)

Table-1: Demonstrate the clinical findings among study sample

Clinical	Freq	%
Palpable mass	105	52.5
Nipplesdischarge	14	7.0
Nippleretraction	8	4.0
Skin change	1	.5
Screening	24	12.0
Massandnipplesdischarge	2	1.0
Maas,Nipple retraction ,Skin changes	2	1.0
Nipple retraction ,Nipplesdischarge	2	1.0
Mass,Skinchanges ,Nipplet,Disgharg	1	.5
Mastalgia	41	20.5
Total	200	100.0

Table (2): Demonstrate the type of breast composition among study sample.(n=200)

Breastcomposition	Frequency	Percent
Fatty composition(A)	35	17.5
Fatty glandular composition(B)	54	27.0
Glandular composition(C)	111	55.5
Total	200	100.0



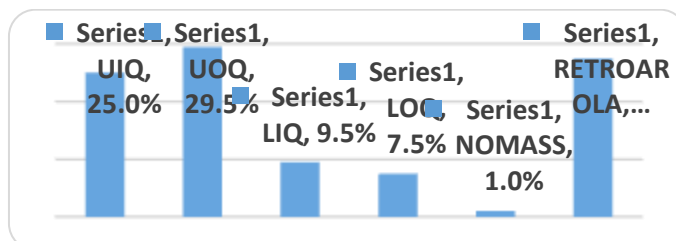
Graph-4: Demonstrate the shape of breast lesion in Ultrasound

Table-3: Orientation the site of breast lesion among study sample.(n=200)

ORIENTATION1	Frequency	Percent
RIGHT breast	96	48.0
LEFT	104	52
Total	200	100.0

Table-4: Orientation the lesion in breast among study sample.(n=200)

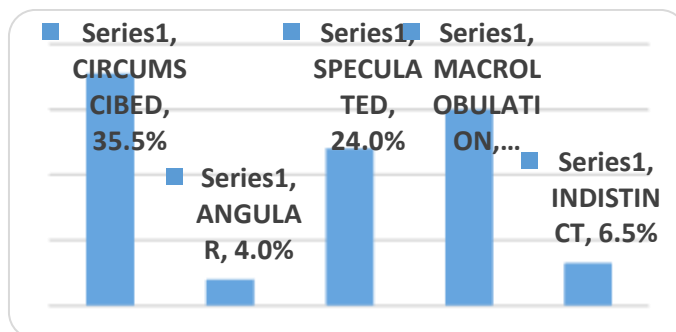
ORINTATIN2	Frequency	Percent
Upper inner quadrant	50	25.0
Upper outer quadrant	59	29.5
Lower inner quadrant	19	9.5
Lower outer quadrant	15	7.5
No mass like	2	1.0
Retroarolar	55	27.5
Total	200	100.0



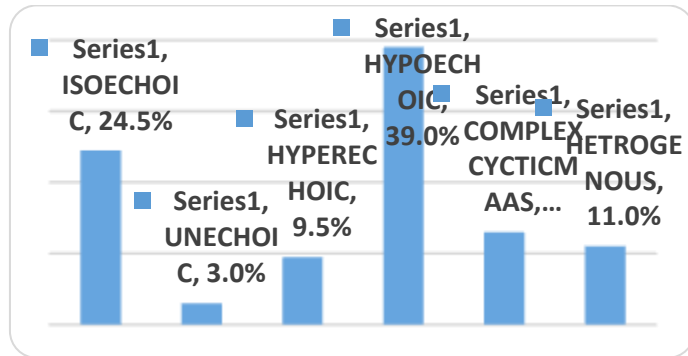
Graph-5: Orientation the lesion in breast among study sample.(n=200)

Table-5: Show the macro calcification seen by ultrasound among study sample .(n=200)

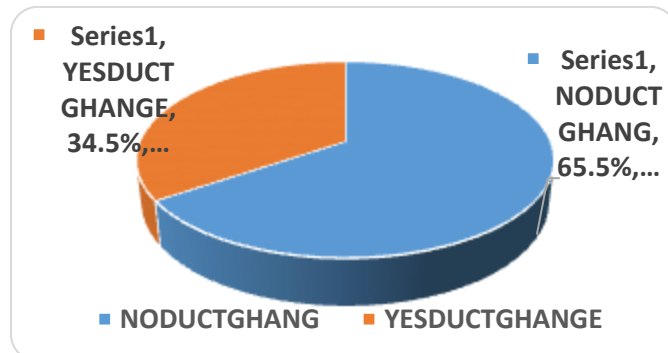
US CALCIFICATIN	Freq	%
No calcification	134	67.0
Presence of calcification	66	33.0
Total	200	100.0



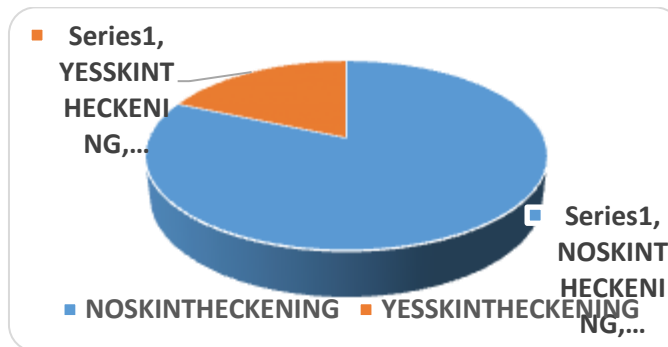
Graph-6: Show the margin of lesion in ultrasound



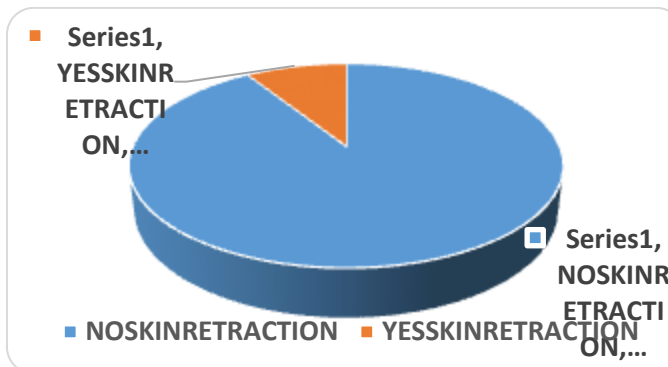
Graph-7: Demonstrate the echo pattern of lesion in ultrasound among study sample.(n=20)



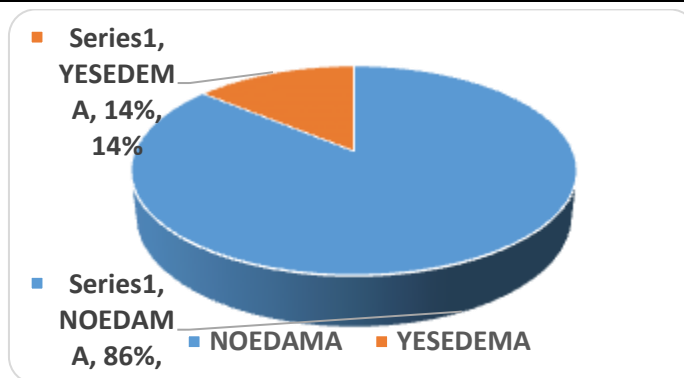
Graph-8: Show the duct change seen in ultrasound among study sample.(n=200)



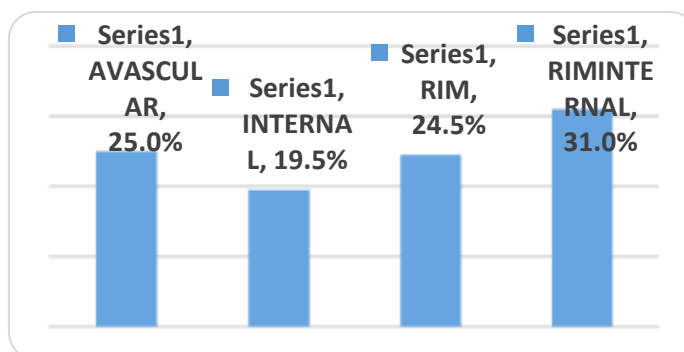
Graph-9: Show the skin thickening seen in ultrasound among study sample (n=200)



Graph-10: Show skin retraction seen among study sample.(n=200)



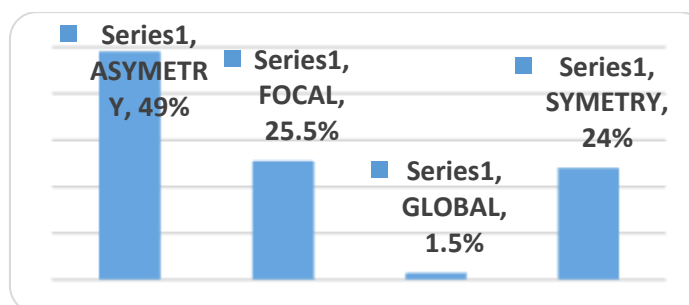
Graph-11: Show skin edema seen among study sample.(n=200)



Graph-12: Demonstrate the vascularity of lesion by ultrasound

Table-6: Show the lesion in tomosynthesis mammography

MMAMMOSHAPE	Freq	%
OVALE	28	14.0
ROUND	40	20.0
IRREGULAR	78	39.0
NOMASS VISULIZE	54	27.0
Total	200	100.0

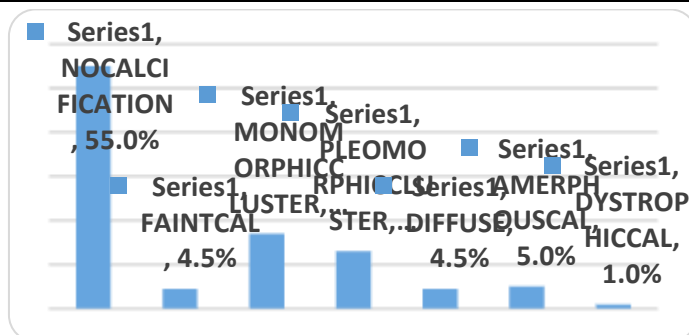


Graph-13: Demonstrate the symmetry density of breast in tomosynthesis mammography

Table-7: Show the archturalditortion in tomosynthesis mammography

ARCHETURALDISTORTION	Freq	%
NOARCHETURALDISTORTION	153	76.5
YESARCHETURALDITORTION	47	23.5
Total	200	100.0





Graph-13: Show the presence, distribution and type of calcification in tomosynthesis mammography

Table-8: Show the (Breast Imaging Reporting and Data System) BIRAD of breast lesion

BIRAD	Freq	%
BIRAD1	8	4.0
BIRAD2	2	1.0
BIRAD3	24	12.0
BIRAD4	108	54.0
BIRAD5	58	29.0
Total	200	100.0

**DISCUSSION**

The current study was aimed to orient the role of imaging (sonography and tom synthesis) in detection of breast lesion. 200 sample of patients who transferred for imaging department for breast imaging were taken. Their age was between 25 and 90 years. From graph one most of sample was in age group of 35-55 years, According to the American Cancer Society, about 1 out of 8 invasive breast cancer develop in women younger than 45, about 2 out of 3 invasive breast cancers are found in women 55 or less so the current result is not a way from the results carried by American Cancer Society. , In fact the aging process is the biggest risk factor for breast cancer because of longer their live so there are more chance for appearance .

Among the sample of this study around 21% had family history of breast lesion a strong family history of breast cancer is linked to having an abnormal gene associated with a high risk of breast cancer, such as the *BRCA1* or *BRCA2* gene also, an abnormal *CHEK2* gene may play a role in developing breast cancer (16,23,25).

The most clinical findings in our sample was palpable mass (52%) , and the less frequent finding was skin change (0.5%), while during study carried by Babatunde A Ayoadein Nigeria the commonest symptoms were, breast lump in 111 patients, (91.7%) and breast pain in 28 patients (23.1%).

Through our sample (n=200) 52% of lesion seen in the left breast Many studies have shown that unilateral breast cancer is more frequent in the left breast than in the right. This has been investigated in the Icelandic Cancer Registry. Information on all but 18 female breast cancer cases diagnosed in the forty-year-

period from 1948 to 1987, a total of 2139 cases, was used. Of these 2011 were unilateral, 1069 were in the left breast, an excess of 13%. Primary breast cancer in both breasts was diagnosed in 81 women, 35 in the left breast first, and 46 in the right breast first breast lumps are a very common complaint for women of all ages. Breast lumps may occur spontaneously or gradually and may be accompanied by other symptoms such as breast pain, changes in the skin or changes in the nipple.

In the current study 52% have palpable mass, compared to literature (20, 21, 24, 26) it was somewhat agree. A breast lump may or may not be noticeable to the patient; normal breast tissue can be quite lumpy in some women and some lumps can be small or located deep in the breast. Special tests such as a mammogram often detect breast lumps that cannot be felt. Over 90% of breast lumps are caused by benign breast disease, a range of non-cancerous conditions.

The breast imaging reporting and data system (BI-RADS) was developed in 1993 and published by the American College of Radiology (ACR) to standardize the reporting of mammographic findings, to clarify its interpretation and to facilitate communication between clinicians. Studies investigating the positive predictive value (PPV) of mammographic features described in the mammography BIRADS lexicon have found it to be useful in differentiating between benign and malignant breast lesions ( 28,29 ).

With recent developments in ultrasound equipment, sonography is now a well established tool in breast imaging, allowing identification of up to 27% of breast masses that are occult on mammography,



especially in women younger than 50 years of age. Compared to our study 66 (33%) have mass of specific shape on upper outer quadrant.

## REFERENCES

1. Berry DA, Cronin KA, Plevritis SK, Fryback DG, Clarke L, Zelen M, Mandelblatt JS, Yakovlev AY, Habbema JD, Feuer EJ. Effect of screening and adjuvant therapy on mortality from breast cancer. *New England Journal of Medicine*. 2005 Oct 27;353(17):1784-92.
2. Hellquist BN, Duffy SW, Abdsaleh S, Björnelid L, Bordás P, Tabár L, Viták B, Zackrisson S, Nyström L, Jonsson H. Effectiveness of population-based service screening with mammography for women ages 40 to 49 years: evaluation of the Swedish Mammography Screening in Young Women (SCRY) cohort. *Cancer*. 2011 Feb 15;117(4):714-22.
3. Tabar L, Gad A, Holmberg LH, Ljungquist U, Fagerberg CJ, Baldetorp L, Gröntoft O, Lundström B, Månson JC, Eklund G, Day NE. Reduction in mortality from breast cancer after mass screening with mammography: randomised trial from the Breast Cancer Screening Working Group of the Swedish National Board of Health and Welfare. *The Lancet*. 1985 Apr 13;325(8433):829-32.
4. Tabar L, Yen MF, Vitak B, Chen HH, Smith RA, Duffy SW. Mammography service screening and mortality in breast cancer patients: 20-year follow-up before and after introduction of screening. *The Lancet*. 2003 Apr 26;361(9367):1405-10.
5. Mandelson MT, Oestreicher N, Porter PL, White D, Finder CA, Taplin SH, White E. Breast density as a predictor of mammographic detection: comparison of interval-and screen-detected cancers. *Journal of the National Cancer Institute*. 2000 Jul 5;92(13):1081-7.
6. Kerlikowske K, Grady D, Barclay J. Effect of age, breast density and family history on the sensitivity of first screening. *JAMA*. 1966;276:33-8.
7. Kopans DB. Digital breast tomosynthesis from concept to clinical care. *American Journal of Roentgenology*. 2014 Feb;202(2):299-308.
8. Niklason LT, Christian BT, Niklason LE, Kopans DB, Castleberry DE, Opsahl-Ong BH, Landberg CE, Slanetz PJ, Giardino AA, Moore R, Albagli D. Digital tomosynthesis in breast imaging. *Radiology*. 1997 Nov;205(2):399-406.
9. Gennaro G, Toledano A, Di Maggio C, Baldan E, Bezzon E, La Grassa M, Pescarini L, Polico I, Proietti A, Toffoli A, Muzzio PC. Digital breast tomosynthesis versus digital mammography: a clinical performance study. *European radiology*. 2010 Jul 1;20(7):1545-53.
10. Good WF, Abrams GS, Catullo VJ, Chough DM, Ganott MA, Hakim CM, Gur D. Digital breast tomosynthesis: a pilot observer study. *American Journal of Roentgenology*. 2008 Apr;190(4):865-9.
11. Gur D, Abrams GS, Chough DM, Ganott MA, Hakim CM, Perrin RL, Rathfon GY, Sumkin JH, Zuley ML, Bandos AI. Digital breast tomosynthesis: observer performance study. *American Journal of Roentgenology*. 2009 Aug;193(2):586-91.
12. Gur D, Abrams GS, Chough DM, Ganott MA, Hakim CM, Perrin RL, Rathfon GY, Sumkin JH, Zuley ML, Bandos AI. Digital breast tomosynthesis: observer performance study. *American Journal of Roentgenology*. 2009 Aug;193(2):586-91.
13. Tagliafico A, Astengo D, Cavagnetto F, Rosasco R, Rescinito G, Monetti F, Calabrese M. One-to-one comparison between digital spot compression view and digital breast tomosynthesis. *European radiology*. 2012 Mar 1;22(3):539-44.
14. Teertstra HJ, Loo CE, van den Bosch MA, van Tinteren H, Rutgers EJ, Muller SH, Gilhuijs KG. Breast tomosynthesis in clinical practice: initial results. *European radiology*. 2010 Jan 1;20(1):16-24.
15. Noroozian M, Hadjiiski L, Rahnama-Moghadam S, Klein KA, Jeffries DO, Pinsky RW, Chan HP, Carson PL, Helvie MA, Roubidoux MA. Digital breast tomosynthesis is comparable to mammographic spot views for mass characterization. *Radiology*. 2012 Jan;262(1):61-8.
16. Tryggvadottir L, Olafsdottir EJ, Gudlaugsdottir S, Thorlacius S, Jonasson JG, Tulinius H, Eyfjord JE. BRCA2 mutation carriers, reproductive factors and breast cancer risk. *Breast Cancer Research*. 2003 Oct;5(5):R121.
17. Rose SL, Tidwell AL, Bujnoch LJ, Kushwaha AC, Nordmann AS, Sexton Implementation of TM in a routine screening practice: an observational study. *AJR Am J Roentgenol*. 2013;200(6):1401-8.
18. Gilbert F, Tucker L, Gillan M, Willsher P, Cooke J, Duncan K, Michell M, Dobson H, Lim Y, Purushothaman H, Strudley C. The TOMMY trial: a comparison of TOMosynthesis with digital MammographY in the UK NHS Breast Screening Programme-a multicentre retrospective reading study comparing the diagnostic performance of digital breast tomosynthesis and digital mammography with digital mammography alone.
19. Conant EF. Clinical implementation of digital TM. *Radiol Clin North Am* 2014;52(3): 499-518.
20. Lourenco AP, Barry-Brooks M, Baird GL, Tuttle A, Mainiero MB. Changes in recall type and patient treatment following implementation of screening digital TM. *Radiology*. 2015;274(2):337-42.
21. Skaane P, Bandos AI, Eben EB, Jepsen IN, Krager M, Haakenaasen U. Two-view digital TM screening with synthetically reconstructed projection images: comparison with digital TM with full-field digital mammographic images. *Radiology* 2014; 271(3):655-63.
22. Svahn TM, Houssami N, Sechopoulos I, Mattsson S. Review of radiation dose estimates in digital

- breast tomosynthesis relative to those in two-view full-field digital mammography. *The Breast*. 2015 Apr 1;24(2):93-9.
23. Shin SU, Chang JM, Bae MS, Lee SH, Cho N, Seo M, Kim WH, Moon WK. Comparative evaluation of average glandular dose and breast cancer detection between single-view digital breast tomosynthesis (DBT) plus single-view digital mammography (DM) and two-view DM: correlation with breast thickness and density. *European radiology*. 2015 Jan 1;25(1):1-8.
  24. Ho JM, Jafferjee N, Covarrubias GM, GhesaniM, Handler B. Dense breasts: a review of reporting legislation and available supplemental screening options. *AJR Am J Roentgenol* 2014;203(2):449–56.
  25. Bernardi D, Ciatto S, Pellegrini M, Anesi V, Burlon S, Cauli E. Application of TMin screening: incremental effect on mammography acquisition and reading time. *Br J Radiol* 2012;85(1020):e1174–8.
  26. Dang PA, Freer PE, Humphrey KL, Halpern EF, Rafferty EA. Addition of tomosynthesis to conventional digital mammography: effect on image interpretation time of screening examinations. *Radiology*. 2014 Jan;270(1):49-56.
  27. Hakim CM, Chough DM, Ganott MA, Sumkin JH, Zuley ML, Gur D. Digital breast tomosynthesis in the diagnostic environment: a subjective side-by-side review. *American Journal of Roentgenology*. 2010 Aug;195(2):W172-6.
  28. TRYGGVADottir L, Tulinius H, Eyfjord JE, Sigurvinsson T. Breast cancer risk factors and age at diagnosis: an Icelandic cohort study. *International journal of cancer*. 2002 Apr 1;98(4):604-8.
  29. Talamini R, Franceschi S, La Vecchia C, Negri E, Borsa L, Montella M, Falcini F, Conti E, Rossi C. The role of reproductive and menstrual factors in cancer of the breast before and after menopause. *European Journal of Cancer*. 1996 Feb 1;32(2):303-10.