

Fracture-Dislocation of Lisfranc: About 20 Cases and Review of the Literature

A. Lagdid*, Ra Bassir, O. Ben Hazim, M. Boufettal, M. Kharmaz, Mo Lamrani, M. Ouadghiri, A. Bardouni, M. Mahfoud, M.S. Berrada

Department of Orthopedic Surgery and Traumatology, Ibn Sina UHC, Mohamed V University, Rabat, Morocco

Original Research Article

*Corresponding author

A. Lagdid

Article History

Received: 15.05.2018

Accepted: 24.05.2018

Published: 30.05.2018

DOI:

10.21276/sjams.2018.6.5.61



Abstract: These traumas are rare. It represents 0.2% of all fractures. Besides early diagnosis, an anatomical and stable reduction is paramount for obtaining a favorable outcome. It is a retrospective study of a series of 20 cases of fractures-dislocation of LISFRANC over a period of 5 years ranging from 2010 to 2017, collected in the orthopedic trauma department of Avicenna Hospital in Rabat. 2 cases benefited from orthopedic treatment: reduction by external maneuver under rachi anesthesia, followed by a plastered boot for a period of 6 weeks. 1 case benefited from a percutaneous Kirschner wiring after reduction of dislocation by external maneuver under rachi anesthesia. 17 cases: were surgically treated: open reduction followed by fixation with Kirschner wires. After a decline of 18 months, we judged: Good results: 6 cases, ie 30%, Bad: in 14 cases, ie 70% (including 10% secondary to insufficient orthopedic treatment and 60% to surgical treatment). In our series 4 patients had septic complications, 2 cases of malunion, no cases of nonunion or bone necrosis. Based on the literature and the functional results of our patients who benefited from fixation by Kirschner wires, the open approach and fixation with screws (and plaques) of acute Lisfranc injuries, enable more precise reduction and superior stability with less secondary displacement.

Keywords: fracture, dislocation, Lisfranc, tarsometatarsal joint.

INTRODUCTION

Since Jaques Lisfranc (1790-1847) described an amputation across tarsometatarsal joints (TMT) during the Napoleonic wars in 1815 [1, 2]. TMT complex injuries have become eponymous with his name.

These traumas are rare. It represents 0.2% of all fractures, but they are often not diagnosed. Particularly when the lesions are purely ligamentous or when they are integrated into a poly-traumatic context [3, 4].

As a result, a theoretical and practical analytical study is essential, with the following objectives:

- The Lisfranc joint fracture-dislocation diagnosis which remains rather rare
- Recall the mechanism and the different anatomopathological classifications.

An update on the various therapeutic aspects and finally a practical application on a retrospective study of 20 Lisfranc fracture-dislocation cases collected

at the orthopedic traumatology service at Avicenne Hospital in Rabat over a period of 5 years.

MATERIALS AND METHODS

But of the study

Our study aims to compare the management of fractures dislocation of LISFRANC with Avicenne orthopedic traumatology department of Rabat with data from the literature and to highlight the adequate diagnostic and therapeutic means.

Study materials

It is a retrospective study of a series of 20 cases of fractures-dislocation of LISFRANC over a period of 5 years ranging from 2010 to 2017, collected in the orthopedic trauma department of Avicenna Hospital in Rabat. Our study includes 20 patients, all diagnosed and treated in urgently.

Epidemiology

- Our series includes: 17Men (85%), 3Women (15%)
- Our series is composed of young adults with an average age of 33 and with extremes of 18 years and 67 years.

- There is a predominance of the right side (11 cases) especially in the context of accidents on public roads, as the right-hander tends to use his right side to protect himself³².
- The causes of injury included traffic accidents in 17 patients and falls from one high place in 3 patients.

Clinical data

Functional signs: Pain: constant in all patients. Functional impotence of the affected limb: absolute in 18 patients, and partial in the other two.

Local Clinical Exam: Finds the Following Signs

Deformation of the foot: present in 5 patients (25%). Localized edema: present in 17 cases (85%). Localized bruising: in 10 cases (50%). Pain on palpation: at all patients (100%). Note the absence of signs of acute ischemia in all patients.

Locoregional and general clinical examination

In search of associated lesions. In our series, we found: Skin lesions: in 7 patients ie 35% of our

series. Associated fractures-dislocation: 6 patients, ie 30%, are polytraumatized. 2 patients ie 10% of cases presented associated locoregional bone lesions, mainly represented by malleolar fractures. 1 case, ie 5% had a head trauma with fractures at a distance: fracture of the leg, femur, and the face.

However, we did not notice any vascular or nerve lesions in all our patients.

Imaging data

All our patients benefited from a X-ray evaluation of face, profile and 3/4, a computed tomography combined with a three-dimensional reconstruction. An unharmed contralateral control has also been put in place.

According to the classification of MEYERSON [5, 6]: 8 cases, ie 40% of Type A (total dislocation) (Figure-1). 6 cases, ie 30% of Type B (partial dislocation), including 2 cases of type B1 (columnaire) and 4 cases of type B2 (spatular). 6 cases, ie 30% of Type C (divergent dislocation).

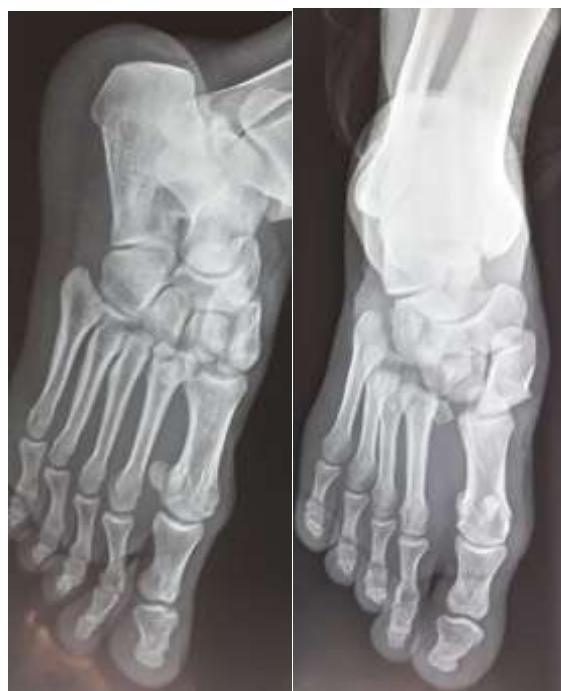

Fig-1: (a, b): A standard X-ray of Face and 3/4 of the right foot showing a fracture dislocation type A of Lisfranc according to Mayerson classification

THERAPEUTIC MANAGEMENT

In our series, all patients were treated in urgently: 2 cases benefited from orthopedic treatment: reduction by external maneuver under rachis anesthesia, followed by a plastered boot for a period of 6 weeks. 1 case benefited from a percutaneous Kirschner wiring after reduction of dislocation by external maneuver under rachis anesthesia. 17 cases: were surgically treated: open reduction followed by fixation with Kirschner wires (Figure-2). The joint was approached by double

incision: 1st at the 1st inter-metatarsal space and 2nd at the 4th inter-metatarsal space. The approach was deep after dissection of the elements of these two spaces. The two incisions meet after a deep detachment without it being necessary to dissect the elements of each space. Immobilization by plaster cast or posterior splint for 6 weeks was systematic, then removal of the latter with the wires at a time.

All our patients received clinical monitoring and periodic radiological examinations in consultation. Rehabilitation has been indicated systematically, but

most of our patients have preferred to continue at home or neglect.

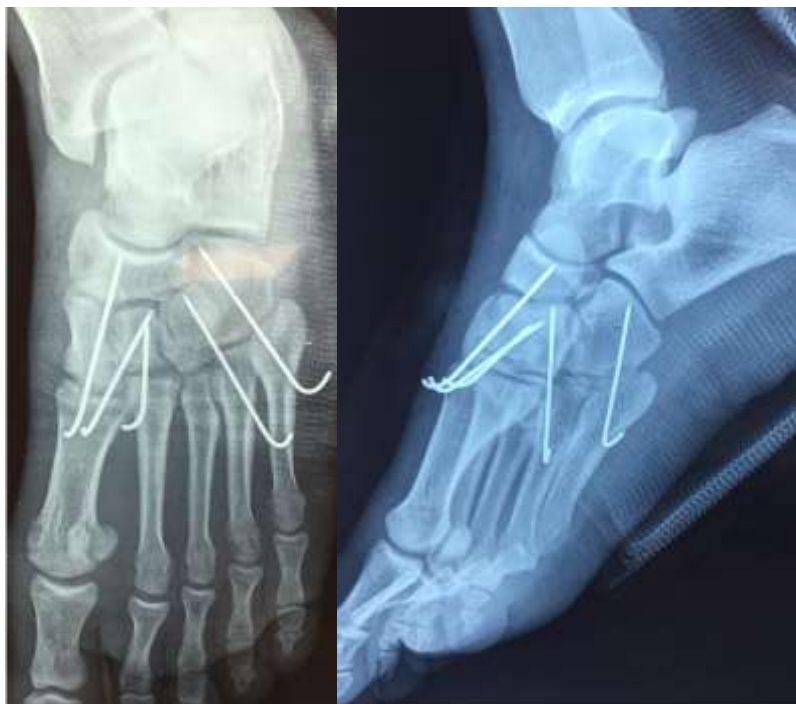

Fig-2: (a, b): Postoperative X-rays of Face and profil of the right foot showing anatomical reduction.

RESULTS

In order to rate our results, we have adopted the criteria of GAY and ERVRAD (see Table 1). The results are listed in: Bad: 0 to 4, Fair: 5 to 9, Good: 10 to 14, Excellent: 15

After a decline of 18 months, we judged: Good results: 6 cases, ie 30%, Bad: in 14 cases, ie 70%

(including 10% secondary to insufficient orthopedic treatment and 60% to surgical treatment).

In our series 4 patients had septic complications, 2 cases of malunion, no cases of nonunion or bone necrosis.

Table-1: GRAY and ERVRAD criteria

	pains	Stability	Mobility	Trophic disorders	Profession
0	permanent	unstable	0	+++	Stop
1	To the function	insecurity	+1/2	Walking	Change
2	Fatigue In Irregular Terrain	Instability Slight irregular	- 1/2	slight	Restraint
3	absent	stable	normal	null	identical

DISCUSSION

Fractures-dislocation of Lisfranc joints are relatively rare with a frequency of 0.1% to 0.9% of all fractures [7, 8]. These estimates may be too low, as between 20% and 40% of these lesions are either neglected or misdiagnosed [9, 10]. If neglected or not treated properly, these fractures-dislocations often result in painful malunion and impaired function [10, 11].

The direct and indirect mechanisms are responsible for injuries to the Lisfranc joint complex. The most common mechanisms are indirect injurie. [12].These can include high-energy injuries, such as those associated with road accidents or falls from

height, or low-energy injuries, such as those sustained during sports activities [13]. Most often it is a combination of longitudinal force applied to the forefoot, which is then subject to rotation and compression [14].

Excessive plantarflexion and abduction forces are the most common indirect mechanisms leading to Lisfranc joint complex injury [15].

Direct injuries are less common and are usually caused by crush injuries in which the bases undergo either dorsal or plantar displacement [6]. These lesions may be associated with severe soft tissue

trauma, vascular compromise, skin compromise and / or compartment syndrome [16, 17].

In 1909, Quenu and Kuss [18] published a classification scheme based on their concept of column and spatula, dividing the lesions into 3 types - homolateral (all metatarsals displacing in the same direction at their bases), isolated (subluxation of 1 or 2 metatarsal bases in one direction while the others remain enlocated), and divergent (displacement of the metatarsal bases in different directions).

Later, Hardcastle and colleagues, [8] in 1982, described a similar classification based on Quenu and

Kuss, dividing injuries into 3 types - A (complete incongruity with complete displacement of all metatarsal bases), B (partial incongruity with one or several displaced metatarsal bases), and C (divergent similar to Quenu and Kuss [18].

More recently, Myerson and colleagues [6] (Figure-3) have modified the classification of Hardcastle and colleagues to divide type B injuries into B1 and B2, where the metatarsal bases can be displaced medially or laterally, respectively. Injuries of type C (divergent) were also divided into C1 and C2 according to the partial or total incongruity, respectively.

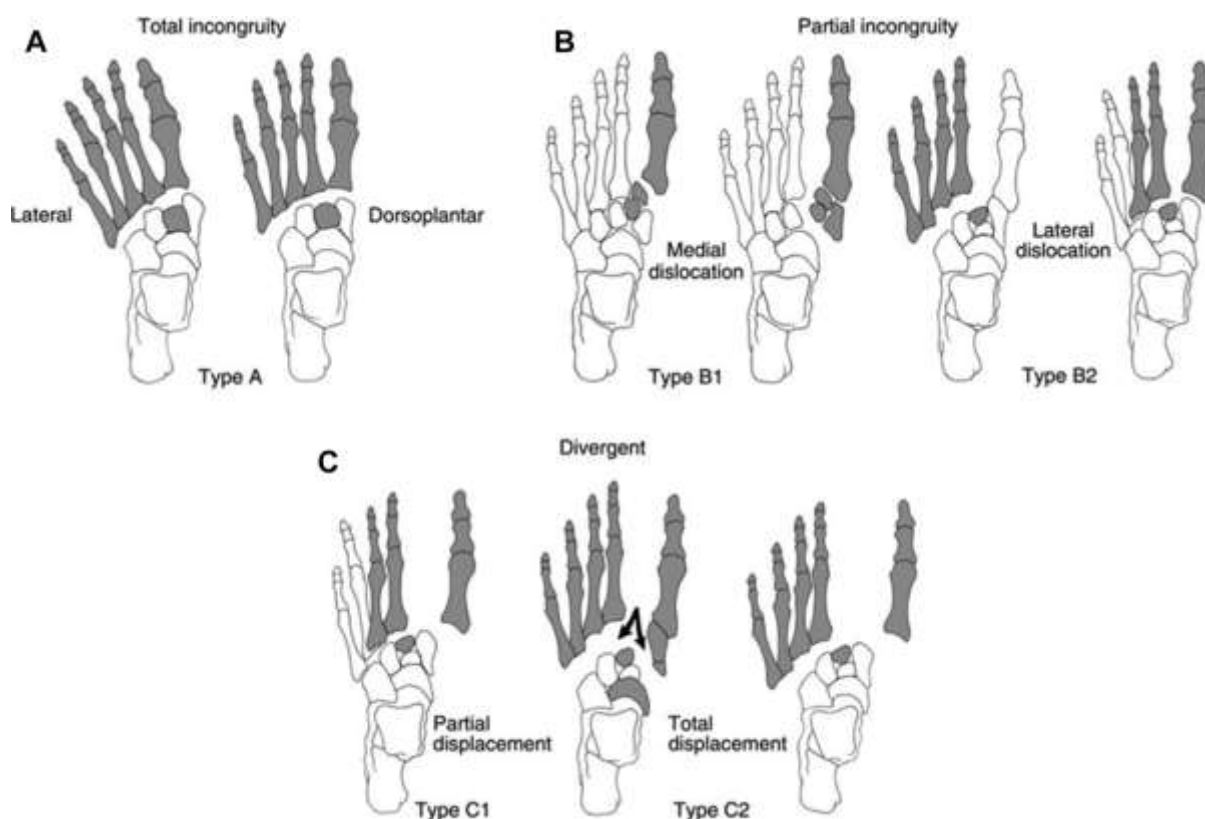


Fig-3: Myerson classification of Lisfranc injuries. (A) Type A injuries, with total incongruity; involve displacement of all five metatarsal bases with or without fracture. These injuries are often referred to as “homolateral”. (B) Type B injuries, with partial incongruity, are where one or more of the articulations at the metatarsal bases remain intact. B1 represents medial dislocation while B2 represents lateral dislocation. (C) Type C is divergent injuries with partial (C1) or total (C2) displacement.

Several studies have shown that the best predictor of a satisfactory result after Lisfranc dislocations is the primary anatomic reduction with internal fixation [9, 6, 19], whereas closed reduction and plaster immobilization often lead to an unacceptable result and frequent redisplacement [10, 6]. The recommended operation ranges from closed reduction and percutaneous fixation [16] to open reduction and internal fixation with Kirschner wires or screws [20, 21, 22, 16, 23] or even primary arthrodesis in case severe comminuted fractures [23, 24] or

ligamentous dislocations [25, 26]. Calder, Whitehouse and Saxby [27] reported significantly lower results if surgical treatment was delayed more than six months after the injury.

The influence of the approach and type of fixation on the accuracy and stability of the reduction of acute tarsometatarsal fracture-dislocations was evaluated in this study.

Kirschner wires and tarsometatarsal fracture-dislocations have a rich history [28, 29]. They are still frequently used for closed or open stabilization after reduction of Lisfranc injuries [30, 31, 32, 33, 34, 19, 35]. Different techniques for Kirschner wire fixation were used, making the comparison of these recent studies difficult.

Secondary displacement or non-anatomical reductions occurred in 13% to 25% [31, 32, 35]. However, these studies often used 5 mm of diastasis as a threshold for non-anatomic reduction or secondary displacement [31, 35], as in the current study a maximum of a 2 mm diastasis between the first and second metatarsal was considered as normal. This largely explains the higher number of non-anatomical reductions (32%) and secondary displacements (21%).

Regarding the functional results when using Kirschner wires, the average American Orthopaedic Foot & Ankle Society midfoot score ranges in the literature between 72 and 81 points (of a maximum of 100 points) [30, 32, 19, 35]. These scores are very similar to rigid immobilization with screws [36, 37, 38, 19, 39], which could imply that despite a positive effect on achieving and maintaining anatomical reduction, the type of fixation does not significantly affect the long-term result; thus, outcome appears more related to the initial trauma.

The advantage of using Kirschner wires is the ease of insertion and removal in open and closed approaches. More extensive secondary surgery is required to remove the implants. Transarticular screw fixation apparently gives more rigid stabilization, but joint damage is important and lies between 2% and 7.6% of the articular surface [40, 41]. An alternative to the transarticular screw is the extra-articular plating, which gives a similar stability [40]. The need to remove implants is still a topic of debate. Screws are frequently removed to avoid breakage [42]. Stabilization should be at least 3 to 4 months. This may be too long for smooth pins, which may show loosening over time [43]. In addition, secondary surgery is associated with additional costs. Weighing the pros and cons of Kirschner wires, Chiodo *et al.*, [43] recommended using Kirschner wires only to stabilize the lateral column and in case of severe comminution.

In conclusion, based on the literature and the functional results of our patients who benefited from fixation by Kirschner wires, the open approach and fixation with screws (and plaques) of acute Lisfranc injuries, enable more precise reduction and superior stability with less secondary displacement.

REFERENCES

1. Cassebaum WH. 13 Lisfranc Fracture-Dislocations. *Clinical Orthopaedics and Related Research*. 1963 Jan 1;30:116-32.
2. Welck MJ, Zinchenko R, Rudge B. Lisfranc injuries. *Injury*. 2015 Apr 1;46(4):536-41.
3. Early JS, Bucholz RW. Lisfranc injuries and their management. *Current orthopaedics*. 1996 Jul 1;10(3):169-73.
4. Faciszewski T, Burks RT, Manaster BJ. Subtle injuries of the Lisfranc joint. *The Journal of bone and joint surgery. American volume*. 1990 Dec;72(10):1519-22.
5. Myerson M. The diagnosis and treatment of injuries to the Lisfranc joint complex. *The Orthopedic clinics of North America*. 1989 Oct;20(4):655-64.
6. Myerson M, Fisher R, Burgess A, Kenzora J. Dislocations of the tarsometatarsal joint. *Foot Ankle*. 1986; 6: 225-42.
7. English TA. Dislocations of the metatarsal bone and adjacent toe. *Bone & Joint Journal*. 1964 Nov 1;46(4):700-4.
8. Hardcastle PH, Reschauer R, Kutscha-Lissberg E, Schoffmann W. Injuries to the tarsometatarsal joint. Incidence, classification and treatment. *Bone & Joint Journal*. 1982 Jun 1;64(3):349-56.
9. Goossens M, De NS. Lisfranc's fracture-dislocations: etiology, radiology, and results of treatment. A review of 20 cases. *Clinical orthopaedics and related research*. 1983 Jun(176):154-62.
10. Zwipp H, Rammelt S, Holch M, Dahlen C. Die Lisfranc-Arthrodesse nach Fehlheilung. *Der Unfallchirurg*. 1999 Nov 1;102(12):918-23.
11. Rammelt S, Schneiders W, Zwipp H. Corrective tarsometatarsal arthrodesis for malunion after fracture-dislocation. *Der Orthopade*. 2006 Apr;35(4):435-42.
12. Desmond EA, Chou LB. Current concepts review: Lisfranc injuries. *Foot Ankle Int* 2006;27(8):653-60.
13. Mantas JP, Burks RT. Lisfranc injuries in the athlete. *Clinics in sports medicine*. 1994 Oct;13(4):719-30.
14. Hatem SF, Davis A, Sundaram M. Your diagnosis? Midfoot sprain: Lisfranc ligament disruption. *Orthopaedics* 2005;28(1):2, 75-7.
15. Myerson MS, Cerrato RA. Current management of tarsometatarsal injuries in the athlete. *J Bone Joint Surg Am* 2008;90(11):2522-33.
16. Myerson MS. The diagnosis and treatment of injury to the tarsometatarsal joint complex. *J Bone Joint Surg Br* 1999;81(5):756-63.
17. Wiley JJ. The mechanism of tarsometatarsal joint injuries. *J Bone Joint Surg Br* 1971;53(3):474-82.
18. Quénu EA. Etude sur les luxations du metatarses (luxations metatarsotarsiennes) du diastasis entre 1^e et le 2^e metatarsien. *Rev. Chir*. 1909;39:1093-134.
19. Richter M, Thermann H, Hüfner T, Schmidt U, Krettek C. Aetiology, treatment and outcome in Lisfranc joint dislocations and fracture dislocations. *Foot Ankle Surg* 2002;8:21-32.

20. Komenda GA, Myerson MS, Biddinger KR. Results of arthrodesis of the tarsometatarsal joints after traumatic injury. *JBJS*. 1996 Nov 1;78(11):1665-76.
21. Randt T, Dahlen C, Schikore H, Zwipp H. Dislocation fractures in the area of the middle foot: injuries of the Chopart and Lisfranc joint. *Zentralbl Chir* 1998;123:1257-66.
22. Arntz CT, Veith RG, Hansen Jr ST. Fractures and fracture-dislocations of the tarsometatarsal joint. *The Journal of bone and joint surgery. American volume*. 1988 Feb;70(2):173-81.
23. Mulier T, Reynders P, Sioen W, Van den Bergh J, De Reymaeker G, Reynaert P, Broos P. The treatment of Lisfranc injuries. *Acta orthopaedica belgica*. 1997 Jun 1;63:82-90.
24. Mulier T, Reynders P, Dereymaeker G, Broos P. Severe Lisfrancs injuries: primary arthrodesis or ORIF? *Foot Ankle Int* 2002;23:902-5.
25. Kuo RS, Tejwani NC, Digiovanni CW, Holt SK, Benirschke SK, Hansen Jr ST, Sangeorzan BJ. Outcome after open reduction and internal fixation of Lisfranc joint injuries. *JBJS*. 2000 Nov 1;82(11):1609.
26. Ly TV, Coetzee JC. Treatment of primarily ligamentous Lisfranc joint injuries: primary arthrodesis compared with open reduction and internal fixation: a prospective, randomized study. *JBJS*. 2006 Mar 1;88(3):514-20.
27. Calder JD, Whitehouse SL, Saxby TS. Results of isolated Lisfranc injuries and the effect of compensation claims. *Bone & Joint Journal*. 2004 May 1;86(4):527-30.
28. Goossens M, De Stoop N. Lisfranc's fracture-dislocations: etiology, radiology, and results of treatment: a review of 20 cases. *Clin Orthop Relat Res*. 1983;(176):154-162.
29. Hesp WL, van der Werken C, Goris RJ. Lisfranc dislocations: fractures and/or dislocations through the tarso-metatarsal joints. *Injury*. 1984;15(4):261-266.
30. Besse JL, Kasmaoui EH, Lerat JL, Moyon B. Tarso-metatarsal fracture-dislocation: treatment by percutaneous pinning or open reduction (a report on 17 cases). *Foot and ankle surgery*. 2005 Jan 1;11(1):17-23.
31. Dudko S, Kusz D, Pierzcha A. Lisfranc injury—fixation with Kirschner wires. *Foot Ankle Surg*. 2004;10:5-8.
32. Korres D, Psicharis I, Gandaifis N, Papadopoulos E, Zoubos A, Nikolopoulos K. Outcome after anatomic reduction and transfixation with Kirschner wires of Lisfranc joint injuries. *Eur J Orthop Surg Traumatol*. 2003;13:85-90.
33. O'connor PA, Yeap S, Noel J, Khayyat G, Kennedy JG, Arivindan S, McGuinness AJ. Lisfranc injuries: patient-and physician-based functional outcomes. *International orthopaedics*. 2003 Apr 1;27(2):98-102.
34. Owens BD, Wixted JJ, Cook J, Teebaga AK. Intramedullary transmetatarsal Kirschner wire fixation of Lisfranc fracture-dislocations. *Am J Orthop*. 2003;32(8):389-391.
35. Sánchez-Gómez P, Lajara-Marco F, Salinas-Gilabert JE, Lozano-Requena JA. Lisfranc fracture-dislocation:screw vs. K-wire fixation. *Rev Esp Cir Ortop Traumatol*. 2008;52:130-136.
36. Kuo RS, Tejwani NC, Digiovanni CW, Holt SK, Benirschke SK, Hansen Jr ST, Sangeorzan BJ. Outcome after open reduction and internal fixation of Lisfranc joint injuries. *JBJS*. 2000 Nov 1;82(11):1609.
37. Loh SY, Soon JL, Verhoeven WJ. Tarsometatarsal joint injuries-review of clinical presentation and surgical treatment. *Medical Journal of Malaysia*. 2005 Mar;60(1):71.
38. Perugia D, Basile A, Battaglia A, Stopponi M, De Simeonibus AU. Fracture dislocations of Lisfranc's joint treated with closed reduction and percutaneous fixation. *Int Orthop*. 2003;27(1):30-35.
39. Teng AL, Pinzur MS, Lomasney L, Mahoney L, Havey R. Functional outcome following anatomic restoration of tarsal-metatarsal fracture dislocation. *Foot Ankle Int*. 2002;23(10):922-926.
40. Alberta FG, Aronow MS, Barrero M, Diaz-Doran V, Sullivan RJ, Adams DJ. Ligamentous Lisfranc joint injuries: a biomechanical comparison of dorsal plate and transarticular screw fixation. *Foot Ankle Int*. 2005;26(6):462-473.
41. Gaines RJ, Wright G, Stewart J. Injury to the tarsometatarsal joint complex during fixation of Lisfranc fracture dislocations: an anatomic study. *Journal of Trauma and Acute Care Surgery*. 2009 Apr 1;66(4):1125-8.
42. Kalia V, Fishman EK, Carrino JA, Fayad LM. Epidemiology, imaging, and treatment of Lisfranc fracture-dislocations revisited. *Skeletal Radiol*. 2012;41(2):129-136.
43. Chiodo CP, Myerson MS. Developments and advances in the diagnosis and treatment of injuries to the tarsometatarsal joint. *Orthopedic Clinics*. 2001 Jan 1;32(1):11-20.