

**Clinical, Laboratory, Radiological & Autopsy Correlation In Brain Tuberculosis**Dr. Mohini Kucheria<sup>1</sup> (Assoc. Prof.), Dr. Sanjay Kucheria<sup>2</sup> (Prof.), Dr. Amit Verma<sup>3</sup> (Prof. & Head),Dr. Saloni Kucheria<sup>4</sup> (Demonstrator), Dr. Arpita Ajmera<sup>5</sup> (P.G. Resident) & Dr. Vivek Kathed<sup>6</sup> (P.G. Resident)<sup>1,3,5 & 6</sup> Dept. of Pathology: Sri Aurobindo Institute of Medical Sciences, Indore<sup>2</sup>Dept. of Surgery: R. D. Gardi Medical College, Ujjain<sup>4</sup>Dept. of Pathology: Amaltas Institute of Medical Sciences, Dewas**Original Research Article****\*Corresponding author**

Dr. Sanjay Kucheria

**Article History**

Received: 02.02.2018

Accepted: 11.02.2018

Published: 18.03.2018

**DOI:**

10.21276/sjams.2018.6.3.13



**Abstract:** Tuberculosis is a major health problem in developing countries. A significant number of patients admitted to the hospitals in our country succumb to tuberculosis of the brain. Central nervous system tuberculosis is an extra pulmonary tuberculosis with higher mortality & morbidity. Tuberculous meningitis (TBM) is the most frequently observed form of CNS tuberculosis. In TBM patients, early diagnosis and adequate treatment are the most important factors that affect mortality & morbidity. In a significant no of patients, the diagnosis of TBM is empirical as auxiliary diagnostic techniques are expensive and mostly inaccessible in developing countries. In the present study, 65 autopsy cases of brain tuberculosis were studied in detail as regards gross and microscopic features and available data of clinical laboratory and radiological findings correlated. In this study tuberculous meningitis was present in 50 cases (77.0%). Tuberculoma in six cases (9.23%). Three of these were associated with tuberculous meningitis. (1) Tuberculous encephalitis was detected in six cases (9.23%) of which four cases were showing concomitant tuberculous meningitis. (2) Tuberculous abscess was seen in two cases (3.0%). (3) A Single Case of choroid plexitis was found (1.53%). The data as regards age and sex incidence, clinical features and variety of morbid anatomical and histopathological changes compared well with other reported series.

**Keywords:** Autopsy, Brain Tuberculosis & Tuberculous Meningitis.

**INTRODUCTION**

It is a well known fact that, tuberculosis is a major health problem in developing countries. A significant number of patients admitted to the hospitals in our country succumb to tuberculosis of the brain.

Central nervous system Tuberculosis is an extra pulmonary tuberculosis with higher mortality & morbidity. Tuberculous meningitis (TBM) [1,8] is the most frequently observed form of CNS tuberculosis. In TBM patients, early diagnosis and adequate treatment are the most important factors that affect mortality & morbidity. In a significant no of patients, the diagnosis of TBM is empirical as auxiliary diagnostic techniques are expensive and mostly inaccessible in developing countries.

Tuberculosis of the brain is a granulomatous infection caused by human type of Mycobacterium tubercle bacilli. It may manifest in several forms like Tuberculous meningitis [3]; tuberculoma; tuberculous encephalitis; tuberculous abscess; internal hydrocephalus and ischemic lesions. Amongst these, tuberculous meningitis forms the major bulk of brain tuberculosis. It is a well known complication resulting from the hematogenous dissemination of tubercle bacilli

from a primary lesion which is usually in the lungs. Though predominantly a disease of infancy and childhood, the incidence is also high in adults as evident in recent reports. Indian studies show the incidence of tuberculous meningitis in patients With tuberculosis to range from 7.4% to 11.8% [12]. If not diagnosed early and if left untreated, the disease has tendency to progress to deep unconsciousness and even a state of decerebration in about 08-12 weeks time. The diagnosis of brain tuberculosis mainly depends upon the clinical features, cerebrospinal fluid examination, x-ray picture, and CT scan.

The morbidity and mortality is decided by age of the patient, his nutritional and socioeconomic status, living and hygienic conditions, virulence of the organisms and immunity of an individual.

An autopsy study of a patient with brain tuberculosis gives an opportunity to the student of

pathology to elucidate the morbid anatomical and histopathological changes comprehensively.

#### AIMS AND OBJECTIVES

- To study the incidence of brain tuberculosis in autopsy cases.
- To study the variables of age and sex and other clinical data.
- To study histopathological changes in different types of brain tuberculosis.
- To compare the data of this series with those of other series.

#### MATERIALS AND METHODS

The definitive diagnosis of TBM is established by the detection and/or the culture of mycobacterium tuberculosis in the CSF. However, long time required for culture & low possibility of detection of bacilli in the CSF delays the diagnosis. In this study, 65 cases were included which were diagnosed as brain tuberculosis at autopsy. These were encountered over a period of 04 & half years i.e. from January 1987 to June 1991.

All brains were fixed in 10-15% formalin for 8-10 days prior to the examination of external surfaces. To study the cut surfaces, coronal slices were made at 1-2 cm thickness of cerebral hemispheres and for cerebellum and brain stem, the horizontal slices were made at 01 cm thickness. Details of the nature of the meningeal exudate were studied, especially at the base and over all the surfaces of Cerebrum, Cerebellum and midbrain. Gross appearances of the arteries of the carotid and basilar system and Circle of Willis were

studied. Gross appearances of parenchymal lesions, e.g. tuberculomas, infarct, edema or any other possible tuberculous lesions were recorded. Hematoxylin and eosin stained slides were examined microscopically in details with the following points:

#### Meninges

Type of exudate, inflammatory reaction, granulomas-epithelioid cells, Langhan's type of giant cells, lymphocytes; and blood vessels - for evidence of vasculitis.

#### Cerebrum

Edema, Spongiosis, glial reaction, ischemia, abscess. While studying Cerebellum and brain-stem, in addition to the above points, small tuberculomas [4] were carefully looked for, being the common site. In each case, sections from all the representative sites of the Cerebrum, Cerebellum and midbrain particularly showing exudate and areas showing morphologic changes were taken.

Besides H & E staining, special stains like AFB, reticulin and GMS stains were done as and when necessary. The available data from the autopsy records in the department was carefully analyzed as regards: Clinical presentation; laboratory investigations (with special reference to CSF examination); x-ray findings and evidence of tuberculosis elsewhere. Besides studying the gross and microscopic pathological changes in brain in detail, an attempt was made to correlate the above data with the clinical findings.

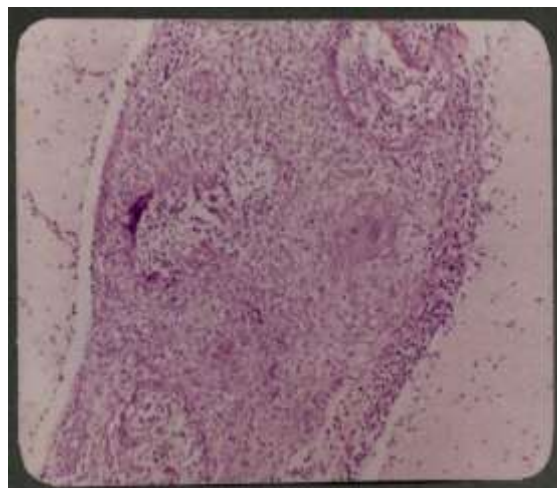


Fig-1: Tuberculous Granulomas

#### OBSERVATIONS AND RESULTS

This study comprised 65 cases of brain tuberculosis diagnosed at autopsy, over the period of 04 & half years, i.e. from January 1987 to June 1991. During this period, total of 2700 autopsies were done in the department. Amongst these, the cases of tuberculosis were 675 (25%). Thus, 65 cases of brain

tuberculosis gave an incidence of 2.4%, of all autopsy cases over the above period, while it was 9.6% amongst the cases of tuberculosis.

The available data as per the records of departmental files was analyzed as regards: age, Sex, clinical features, radiological examination, CSF examination reports etc.

**Table-1: Age & Sex distribution of brain tuberculosis (65 autopsies)**

Age in years	0-10	11-20	21-30	31-40	41-50	51-60	61-70	Total	%
Male	15	04	07	06	07	04	01	44	67.7
Female	06	04	05	02	04	00	00	21	32.3
Total	21	08	12	08	11	04	01	65	100

It can be observed from the above table that the maximum incidence (32.3%) was in the first decade

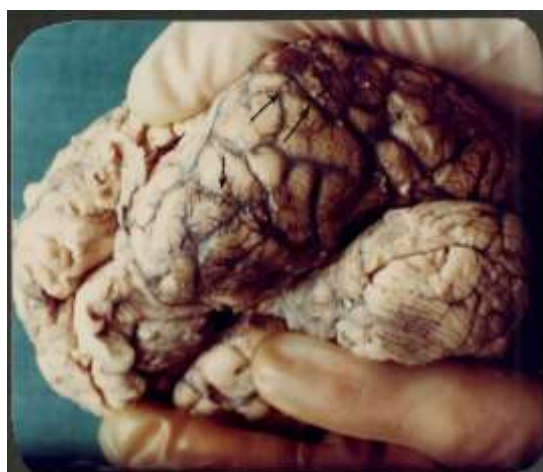of life, while it was lowest (1.5%) in the seventh decade of life.

**Table-2: Histopathological classification of brain tuberculosis**

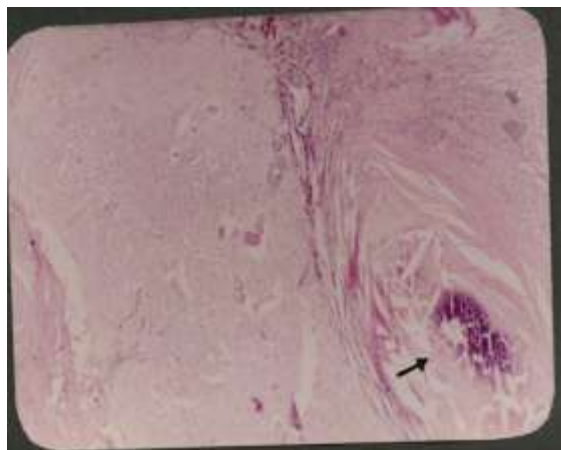
Disease	Number	Percentage
Tuberculous meningitis	50	77.00
Tuberculoma	03	4.60
Tuberculous encephalitis	02	3.07
Choroid plexitis	01	1.53
Tuberculous abscess	02	3.06
Tuberculous meningitis with tuberculous encephalitis	04	6.14
Tuberculous meningitis with tuberculoma	03	4.60
<b>Total</b>	<b>65</b>	<b>100</b>

In the present study, 50 (77%) cases of tuberculous meningitis were encountered out of which in 40 cases (80%) it was predominantly basal in location. The character of the exudate varied from minimal to thick plaque like (plastic). Tubercles were seen in almost all the cases especially along the vessels at the base of brain. Microscopically, fibrin; granulomas comprising Langhan's type giant cells, epithelioid cells, lymphocytes; and vasculitis were observed. The meninges showed proliferation in some cases, while there was perivascular inflammatory infiltrate of lymphocytes and macrophages in most of the cases. In very few cases, infiltration of parenchyma by inflammatory cells was seen. The CSF picture was

typical in majority of the cases showing rise in proteins and cells, predominantly lymphocytes. In most of these cases the diagnosis was suspected clinically. Pulmonary tuberculosis was found in 21 cases. Out of these 50 cases of tuberculous meningitis, 32 were males while 18 were females. In this study, six cases of tuberculoma<sup>[5]</sup> were encountered. Out of these six cases, three were associated with tuberculous meningitis. Male to female ratio was 2:1. The four tuberculomas were situated in the cerebellum (infratentorial) and two were located in the cerebrum (supratentorial). In most of the cases, they were multiple in number (more than 3). The size ranged from 4 mm to 2 cm. They were grayish white in colour.



**Fig-2: Cerebral Hemispheres showing multiple tubercles (arrows) in case of TBM**



**Fig-3: Tuberculoma with Calcification & Fibrosis**

Case (50 years old male), tuberculoma was calcified. The diagnosis was suspected clinically by CT scan. The CSF picture was not typical.

Microscopically, they revealed large areas of Caseation in the Centre surrounded by multiple giant Cells predominantly foreign body type. The presence of marked fibrosis suggested chronic infection. Calcification was seen in one case. Psammoma bodies were also identified. In four cases, primary pulmonary focus could be identified. History of anti-tuberculous drugs taken in the past was obtained. This study revealed two cases of tuberculous abscesses. The age was 9 years and 2 years, respectively. Both were

females. The abscesses were situated in the right frontal and occipital lobe in one case and it was occipital in the other. The size of larger abscess was 5 x 4cm and that of the Smaller was 3x3 cm. The Contents were pus like. Associated hydrocephalus was present in one case, in the form of dilated ventricles leaving behind only the rim of cerebral Cortex. The Wall showed tuberculous granulomas. In both these Cases, active pulmonary tuberculosis was noted.

The clinical signs and symptoms varied depending upon the Organ or organs involved and severity of the disease. The Common symptomatology as per the records available is shown in table-02.

**Table-3: Showing frequency of symptoms in brain Tuberculosis**

Symptoms	No. of Patients	Percentage
Fever	41	63.00
Headache	26	40.00
Vomiting	19	29.20
Convulsions	14	21.50
Altered sensorium	22	33.80
Unconsciousness	11	16.90
Hydrocephalus	07	10.80

Fever, headache and altered sensorium were most commonly occurring symptoms

Amongst the histopathological changes, (table-6) infiltration by lymphocytes topped the list (90.8%), followed by the presence of epithelioid cells (75.4%), perivascular inflammatory infiltrate (63.0%), Oedema (61.5%), giant Cells (58.5%), granulomas (50.8%) etc. Vasculitis was present in 27.7% of cases. It was ranging from thickening of blood vessels to the panarteritic

changes. Exudate was seen in the form of fibrin. Glial reactions in the form of astrocytosis, oligodendrogliosis and myelin loss were encountered Collectively in 35.4% of cases. Caseation was seen in 33.8% of Cases. Spongiosis was the prominent feature of encephalopathy.

**Table-4: Frequency of microscopic changes in brain tuberculosis**

Histopathological	No. Of Cases	Percentage
Granulomas	33	50.50
Giant Cells	38	58.50
Epithelioid cells	49	75.40
Lymphocytes	59	90.80
Caseation	22	33.80
Exudate	16	24.60
Vasculitis	18	27.70
Perivascular inflammatory infiltrate	41	63.00
Oedema	40	61.50
Spongiosis	09	13.80
Glial reaction	23	35.40
Fibrosis	06	9.20

CSF examination records revealed typical picture of tuberculous meningitis in 80% of cases i.e. 52 cases in which proteins were raised above 80 mg% and the highest value was 1.5gm%.

The sugar was below 45 mg% and cells were increased i.e. above 100/cmm. The highest Cell Count was 600/cmm (Lymphocytosis). The Chlorides Were decreased.

In 17% of cases, atypical picture was seen in the form of deviation of typical CSF findings. In some, proteins were raised while the Cells were not raised proportionately and vice versa. 3% of cases showed normal CSF findings out of which onerevealed a calcified tuberculoma. AFB were positive in Smears of 6 cases.

**DISCUSSION**

Incidence in general - In the present study of 65 cases of brain tuberculosis, the incidence was 2.4% of all autopsies [11] over the 4% year period while it was 9.6% amongst the cases of tuberculosis. This is within the range of 7.4% - 11.8% as recorded by Indian studies.

The frequency of TBM is closely related with the incidence of primary infection with the tubercle bacilli. Khatua, S.P. [13] in a study at Medical College and Hospital, Calcutta, have reported tuberculous meningitis in 231 cases out of 5851 admitted cases giving an incidence of 4%. Ramchandran, R.S [14] in a study at Thanjavur Medical College Hospital, Tamilnadu in a study extending from 1964 to 1969 have reported the incidence of TB infection in 2554 (1.4%) of total indoor admissions and out of these 288 (11.2%) were patients of TBM.

Udani, P.M. [21] have reported that 7.7% of total admitted cases were having illness of tuberculous etiology of which 29.02% were cases of TBM. In the series reported by Benakappa [6] from Vani Vilas Hospital (Bangalore, there were 152 (4.28%) cases of tuberculous etiology out of total of 3652 cases admitted

to the pediatric wards. Out of these 72 cases 47.4% were TBM. Auerbach, O [15] in the United States have reported that TBM was the cause of death in 4.6% of all the autopsies.

Most of the reports showed highest incidence in first 3 years of life in paediatric [7] population and 2nd or 3rd decade of life in adult population and also a male predominance. Thus, it is observed that the results of present study are comparable with those of others. In the present study, 6 cases of tuberculomas were observed (9.23%) of which 3 cases were associated with TBM. The age ranged from 2 years to 50 years. M: F was 5 : 1.

Dastur reported that 47% of ICSOL in children [9] were tuberculomas. In Ramamurthi's [16] series the incidence was about 30%. Scott and Graves [17] observed in a study of 815 cases, that the maximum occurrence was amongst the patients below 10 years, the incidence remaining more or less constant from the 10-40 age group but showed a definite decline towards higher age groups and was almost nonexistent beyond the sixth decade. Jaffe and Schultz [18] observed that tuberculomas producing symptoms of cerebral tumors occurred at all ages. On the other hand tuberculomas which were associated with the manifestation of meningitis occurred in younger groups.

Wakely [19] encountered 60% tuberculomas in patients with manifestations of intracranial tumors below the age of 23 years. The youngest patient of tuberculoma of the brain [10] was aged 23 days [20] and the oldest patient was aged 70 years [2].

**Gross and histopathology of brain tuberculosis**

Tuberculous, meningitis - Grossly the brains of cases of tuberculous meningitis showed exudate over meninges in some cases and hazy and thickened adhesive meninges in others. The exudate was prominent at the base of brain (80%), extending along the cerebral vessels. Tubercles were seen in a few cases.

The arteries of the basilar and Circle of Willis showed exudate on external surface. They were thickened and frank tubercles were also noted rarely. In some cases, exudate was dense enough to burry or compress the larger arteries. In the present study 18 cases showed vasculitis. Microscopically, periarteritis, panarteritis, fibrinoid necrosis and subintimal fibrosis were noted with variable frequency. Perivascular infiltration by lymphocytes and plasma cells was seen. Findings in the present study correlate With those of P.N. Tandon and Phatak, S.N. [25] and Dastur and V. S. Lalitha [21]. In spite of the vasculitis, no case of infarct was detected in the present study.

**Tuberculoma** - This study revealed 6 cases of tuberculomas. In 3 cases TBM was accompanied. The majority (4) of them were situated in the infratentorial region being Common in children than in adults. Two were supratentorial, both were adults. In general, tuberculomas favour the infratentorial location Dastur and Desai [22]. The multiplicity of the tuberculomas can be explained by their hematogenous origin Vimala and Dinakar [23].

**Brain oedema** - 40 cases showed Combined gross and microscopic evidence of edema. The association with tuberculoma and tuberculous encephalopathy was noted. Macroscopic evidence of frank haemorrhages in the white matter of cerebrum and cerebellum constituting a form of haemorrhagic encephalopathy as observed by Dastur, D.K., [21] was not found in any case in this study. Noninfarctive oedematous necrosis of the white matter, especially in the perivascular region, is also observed by Dastur, D.K., [21], which was not seen in any Case in the present study.

**Tuberculous abscesses** Were encountered in two Cases in the present study. According to Gajendra Sinh and Pandya [24], tuberculous abscess is an uncommon entity, 3 Cases out of 70 cases and Arseni has reported one case out of 201 cases. Thus, the findings of present study can be very well correlated with that of other series.

**Choroid plexitis** - In the present study, a Single Case of choroid plexitis was encountered. It was grossly noticeable in the form of frank granular tubercles over the Ventricular surface Comparable with Dastur, D.K. [21]. Microscopically is similar to that of tuberculous meningitis.

**Hydrocephalus** - In the present study, it was seen in 7 cases (10.8%). It was bilateral in all these Cases. In 5 cases, it was massive and causing marked brain atrophy. Three were Children and four were adults, the male to female ratio being 5:1. As hydrocephalus is one of the most important mechanisms of brain damage, it should be prevented by an early diagnosis and adequate treatment

With anti-tubercular drugs and Steroids. Surgical treatment may be done if it is established and severe. Hydrocephalus may occur as early as 10 days probably due to increased secretion of CSF.

In the present study, Even though most of the cases were in advanced stage of the disease, the only 7 (10.8%) cases showed full blown hydrocephalus. But diffuse edema of brain was detected in 40 cases (61.5%). Dastur, D. K. [21] have quoted that 40% of advanced cases in their study did not show hydrocephalus. This study of 65 autopsies of tuberculosis of brain spanned over a short period of 04 & half years included almost all histopathological and morbid anatomical variants. By and large, the findings were in agreement with those of larger series reported by other workers.

## SUMMARY AND CONCLUSIONS

In the present study, 65 autopsy cases of brain tuberculosis were studied in detail as regards gross and microscopic features and available data of clinical and radiological findings correlated.

In this study - tuberculous meningitis was present in 50 cases (77.0%).

- Tuberculoma in six cases (9.23%). Three of these were associated with tuberculous meningitis.
- Tuberculous encephalitis was detected in six cases (9.23%) of which four cases were showing concomitant tuberculous meningitis.
- Tuberculous abscess was seen in two cases (3.0%)
- A Single Case of choroid plexitis was found (1.53%).

The data as regards age and sex incidence, clinical features and variety of morbid anatomical and histopathological changes compared well with other reported series.

## REFERENCES

1. Agarwal VK, Kumar PC. A follow up of study of treated Cases of TBM. Ind. 1969; Paed. 6, 291.
2. Asenjo A, Valladares H, Fierro J. Tuberculomas of the brain: report of one hundred and fifty-nine cases. *AMA Archives of Neurology & Psychiatry*. 1951 Feb 1; 65(2):146-60.
3. Auerbach O. Tuberculous meningitis: correlation of therapeutic results with the pathogenesis and pathologic changes. I. General considerations and pathogenesis. *American review of tuberculosis*. 1951 Oct; 64(4):408.
4. Bannister CM. A tuberculous abscess of the brain: Case report. *Journal of neurosurgery*. 1970 Aug; 33(2):203-6.
5. Bedi HK, Devpura JC, Bomb BS. Clinical tuberculoma of pons presenting as Foville's syndrome. 1973; 61: 184-185.

6. Berry JN, Subhedar BJ. Diagnosis and treatment of tuberculous meningitis. *J. Ass. Phys. India.* 1957;191:281-6.
7. Bhakoo ON, Gupte SP. Tuberculosis in children. *Indian journal of pediatrics.* 1969 Mar 1;36(3):65-70.
8. Bombicci. Quoted by Wilson; 1902.
9. Brain L, Walter JN. *Brains disease of the nervous system*, 7th ed. Oxford University Press; 1969: 367-377
10. Brigendra KG. TBM in children. *Ind. Paed.* 1977; 44-87.
11. Cabrall SA. Tuberculoma of the brain, *Ceylon Med. J. II*, 1966; 87.
12. Courville CB, Rosenvold LK. Intracranial Complications of Infections of Nasal Cavities and Accessory Sinuses: A Survey of Lesions Observed in a Series of Fifteen Thousand Autopsies. *Archives of Otolaryngology.* 1938 Jun 1;27(6):692-731.
13. Spillane JD. *Tropical neurology.* Tropical neurology.. 1973.
14. Khatua SP. Tuberculous Meningitis in Children. Analysis of 231 Cases. *Journal of the Indian Medical Association.* 1961;37(7):332-7.
15. Ramachandran RS. TBM review of 288 cases in children. *Ind. Jr. of Paed.* 1970; 37-85.
16. Auerbach O. Tuberculous meningitis: correlation of therapeutic results with the pathogenesis and pathologic changes. II. Pathologic changes in untreated and treated cases. *American review of tuberculosis.* 1951 Oct;64(4):419-29.
17. Ramamurthi B. Experiences with tuberculomas of the brain. *Indian J. Surg.* 1956;18:452-5.
18. Scott E, Graves GD. Tuberculoma of the brain with a report of 4 cases. *Amer. Rev. of Tuberculosis.* 1933; 27: 171-192.
19. Jaffe KH, Schultz A. The relations between tuberculomata of the CNS and tuberculous changes in other organs. *Amer. Rev. Tuberc.* 1936; 33: 302-312.
20. Wakely PG. Some observations on tuberculomas of the brain. *Brit. J. Tubere.* 1937; 33: 75-79.
21. Zuelch KJ. *Brain tumours: Their biology and pathology.* New York, Springer. 1957.
22. Dastur DK, Lalitha VS, Udani PM, Parekh US. The brain and meninges in tuberculous meningitis-gross pathology in 100 cases and pathogenesis. *Neurology India.* 1970 Jun;18(2):86.
23. Dastur DK, Udani PM. The pathology and pathogenesis of tuberculous encephalopathy. *Acta neuropathologica.* 1966 Dec 1;6(4):311-26.
24. Vimala J, Dinakar I. Tuberculomas of the Brain. 1972.
25. Sinh G, Pandya SK, Dastur DK. Pathogenesis of unusual intracranial tuberculomas and tuberculous space-occupying lesions. *Journal of neurosurgery.* 1968 Aug;29(2):149-59.
26. Tandon PN, Pathak SN. Tuberculosis of the central nervous system. In *Tropical neurology 1973* (pp. 37-62). Oxford University Press, London.