

## Handy and Pocket Friendly Method for Retinal Photography

Dr. Shweta Walia<sup>1\*</sup>, Dr. Ayush Mehta<sup>2</sup>, Dr. (Prof.) Vijay Bhisare<sup>3</sup>, Dr. P.Rawat<sup>4</sup>, Dr. N Kori<sup>5</sup>

<sup>1</sup>Assistant Professor, Department of Ophthalmology, MGMMC, MYH, Indore, India

<sup>2</sup>Resident, Department of Ophthalmology, MGMMC, MYH, Indore, India

<sup>3</sup>Department of Ophthalmology, MGMMC, MYH, Indore, India

<sup>4</sup>Department of Ophthalmology, MGMMC, MYH, Indore, India

<sup>5</sup>Department of Ophthalmology, MGMMC, MYH, Indore, India

### Original Research Article

**\*Corresponding author**  
Dr. Shweta Walia

#### Article History

Received: 16.03.2018

Accepted: 25.03.2018

Published: 30.03.2018

#### DOI:

10.21276/sjams.2018.6.3.98



**Abstract:** India is a developing country with majority of its citizens belonging to low or moderate socioeconomic class. Patients of retinal diseases from these groups find it an economical burden to go for fundus photograph on every follow up for progressive retinal diseases. The purpose of this study is to devise an economic technique of fundus photography to reduce the diagnostic burden in cases of progressive retinal disease. We have innovated an easy and economic technique of fundus photography using smart phone and 20 D BIO lens .We present 20 cases of various retinal diseases whose fundus photographs were taken using this technique.

**Keywords:** fundus photography, smart phone, 20 D BIO lens, retinal disorders.

### INTRODUCTION

The ever increasing popularity and availability of smartphones and the rapid advances in technology for capturing and sharing images with them have resulted in the expanding use of smartphones as a clinical-imaging device in ophthalmology. This has been facilitated by the ease of use and portability of the smartphones and the already extensive mobile-phone networks, and it presents a unique opportunity for applications such as telemedicine. Fundus photography is an essential part of ophthalmology practice. Acquisition of high-quality fundus images requires a combination of appropriate optics and illumination usually in the form of a condensing lens and a coaxial light source. This is part of the reason for cost of a commercial fundus camera. We describe in detail a relatively simple, cost effective & compliant technique of fundus photography using a smartphone and 20 D lens.

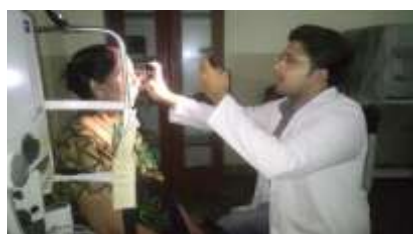### TECHNIQUE

Smartphone fundus images were captured with an iPhone6 & samsung phones and a 20D lens. By using the coaxial light source of the phone, this system worked as an indirect ophthalmoscope that captured a digital image of the fundus in the smartphone camera. This technique of smartphone fundus photography involved multiple steps that are described in detail below. The technique is simple, yet it may take a few attempts to master since the user must learn to readjust the filming distance for focusing with the 20D lens while looking into an inverted image of the fundus on the phone screen. In addition, since the camera lens is usually located in the corner of the smartphone and the digital display is in the center of the phone, the parallel but skewed alignment necessitated by this displacement required some practice to get the fundus images in the center of the screen . Good pupillary dilation prior to filming was ideal as this allowed for easier imaging of the fundus. The phone light source (covered with a piece glass of rayban sunglasses) and camera were used

by the operator as an indirect ophthalmoscope to create a digital image. For most images, we used a 20D lens for focusing the light on the patient's retina in the clinic or emergency room setting. The video recording was activated, and a video of the fundus was captured on the phone screen. The exposure was toggled to the desired area of the fundus on the screen with the filming hand until the fundus was filmed successfully. Since this has to be done with one hand (the other hand is holding the 20D lens), we found that holding the smartphone horizontally with the camera lens up and using the touch screen with the thumb worked the best .The method involved playing the video and taking a snapshot (click on the camera button). Finally, the high-quality images from the patients were ready to be archived in the medical record or used for telemedicine.



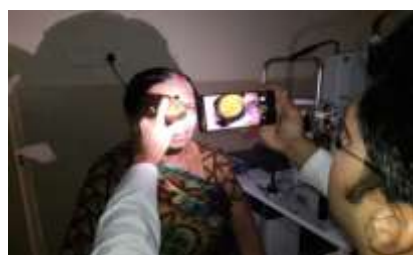**Fig-1: Flash light covered with glass piece from sunglasses**



**Fig-2: Technique**



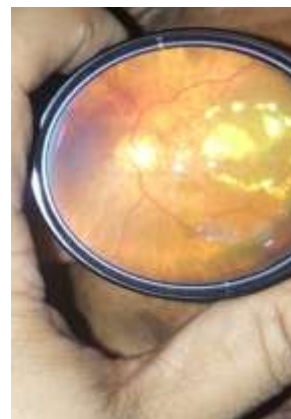**Fig-3: Ophthalmic assistant capturing fundus photos**



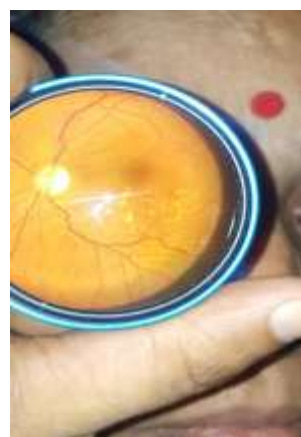**Fig-4: Taking snapshot while videography**

## RESULTS

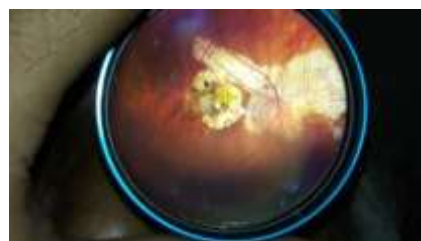
The described technique of smartphone fundus photography with the use of iPhone 6 or Samsung phones & 20D lenses was able to capture excellent, high-quality fundus images. Excellent results were achieved with the 20D lens. We found that even first-year ophthalmology residents (who were not comfortable with indirect) and ophthalmic assistants were also able to master this technique in relatively short period.



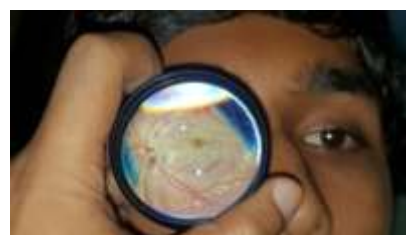**Fig-5: Circinate retinopathy**



**Fig-6: Old superio-temporal brvo with csme**



**Fig-7: High myopic fundus with chorioretinal atrophy**



**Fig-8: Optic nerve avulsion with crao**

## DISCUSSION

The iPhone 4 light source, when used with a 20D condensing lens for smartphone fundus photography using the described technique, had been previously tested and found to be well within the safety standards for human eyes. Kim *et al.* showed that the light levels (without decrease using the app or the paper tape) were 150 times below the thermal hazard limit

and 240 times below the photochemical hazard limit set by the International Organization for Standardization and 10 times below the levels produced by the commercially available Keeler Vantage Plus LED indirect ophthalmoscope[3]. In addition, as described in the Techniques section, we always used a piece of glass from rayban sunglasses over the light source to significantly reduce the light for video recording. Therefore, we were working at a level of light intensity and energy well below what was measured in the Kim et al. paper. Smartphones are now being used more routinely in ophthalmology to document patient's ocular conditions. The described technique provided a relatively simpler and higher quality way to more consistently produce excellent images of a patient's fundus [6]. This technique has been extremely helpful for us in the emergency department setting, in inpatient consultations, and during examinations under anesthesia as it provided a cheaper and portable option for high-quality fundus-image acquisition for documentation and consultation [5]. This technique is well tolerated in awake patients most likely since the light intensity used is often well below that used in standard indirect ophthalmoscopy [3].

#### **CONCLUSION**

The currently described technique was able to take consistently high-quality fundus photographs in patients using a smartphone & 20 D lens. It is relatively simple to master, is relatively inexpensive, and can take advantage of the expanding mobile-telephone networks for telemedicine. We expect that the quality of the images achieved using this technique will continue to improve with availability of higher-resolution cameras with larger sensors and better image stabilization that are being incorporated into newer smartphones.

#### **REFERENCES**

1. Lamirel C, Bruce BB, Wright DW, Newman NJ, Biousse V. Nonmydriatic digital ocular fundus photography on the iPhone 3G: the FOTO-ED study. *Archives of ophthalmology*. 2012 Jul 1;130(7):939-40.
2. Bastawrous A. Smartphone fundoscopy. *Ophthalmology*. 2012 Feb 1;119(2):432-3.
3. Kim DY, Delori F, Mukai S. Smartphone photography safety. *Ophthalmology*. 2012 Oct 1;119(10):2200-1.
4. International Standard, ISO, 15004-2.2, Ophthalmic Instruments, Light Hazard Protection, International Standards Organization (ISO), Geneva, Switzerland, 2007.
5. Lord RK, Shah VA, San Filippo AN, Krishna R. Novel uses of smartphones in ophthalmology. *Ophthalmology*. 2010 Jun 1;117(6):1274-.
6. Chhablani J, Kaja S, Shah VA. Smartphones in ophthalmology. *Indian journal of ophthalmology*. 2012 Mar;60(2):127.