

## **Descriptive Analysis of Post-Operative Complications of Stoma Closure Cases**

**Dr. Rajendra Prasad Bugalia<sup>1\*</sup>, Dr. RK Jenaw<sup>2</sup>, Dr. Ranjan Lamba<sup>3</sup>**

<sup>1</sup>Assistant Professor, Department of Surgery, SMS Medical College, Jaipur India

<sup>2</sup>Senior Professor & Head of Department, Department of Surgery, SMS Medical College, Jaipur India

<sup>3</sup>Medical Officer, Department of Surgery, SMS Medical College, Jaipur India

### **Original Research Article**

#### **\*Corresponding author**

*Dr. Rajendra Prasad  
Bugalia*

#### **Article History**

*Received: 15.03.2018*

*Accepted: 25.03.2018*

*Published: 30.03.2018*

#### **DOI:**

10.21276/sjams.2018.6.3.74



**Abstract:** Formation of an intestinal stoma is frequently a component of surgical intervention for diseases of the small bowel and colorectal pathology. Loop ileostomies are generally formed in colorectal surgery in order to defunction distal enteric disease or anastomoses or where the primary repair of small bowel perforation not feasible due to poor small bowel conditions. Closure of a loop ileostomy is a relatively simple procedure although many studies have demonstrated high morbidity rates following it. Methods to reduce the number of complications such as timing of closure or different surgical closure techniques are investigated. The aim of this study was to evaluate the experience of post-operative complications of stoma closure and to identify potential risk factors for postoperative complications. Although the mortality rate after the reversal of ileostomy is 0.1- 4%. Paralytic ileus, wound infection and vomiting remain the most common complications. A particular complications increase medical costs, prolong hospitalization time, and increase the need for outpatient care as well as the risk of late complications such as incisional hernia.

**Keywords:** Stoma Closure, Diversion ileostomies, Loop ileostomy, Postoperative complications.

### **INTRODUCTION**

Diverting loop ileostomy is useful for reduction of the consequences of an anastomotic leak and is considered by some authors to reduce the incidence of anastomotic complications [1-3]. Ideally a temporary stoma lowers the operative risk, helps preserve life, causes no complications, and is closed as soon as possible and without complications.

The most common intestinal stomas are ileostomies and colostomies; either end or loop stomas [4-6]. Reversal of a loop stoma can be carried out under spinal or general anesthesia by intraperitoneal closure. The operation is easier to perform if a period of at least 6 weeks is allowed to elapse between formation of the stoma and reversal so that there is time for edema and inflammatory adhesion to settle. The freshened edges of the enterotomy can be anastomosed or a resection of a certain length of the proximal and distal ends of the stoma is done and they are anastomosed [7-9]. Once the stoma are reversed, the loop is returned to the abdominal cavity and the abdominal muscles are closed by interrupted synthetic absorbable or non-absorbable sutures. The skin may be left open or just one or two loose are put to facilitate drainage and prevent infection. For the end stomas, laparotomy is carried out, the closed distal stump is identified and a simple end – to – end anastomosis is performed after adequate mobilization and freshening of both the ends. The anastomosis can be performed in single layer interrupted silk; the preferred method of the surgeon

[10-12]. Complications after loop stoma closure include systemic problems associated with any abdominal surgery such as cardio – respiratory complications in addition to specific post reversal complications such as abdominal distension, ileus, surgical site infection, anastomotic leak (enter cutaneous fistula), hemorrhage (intraperitoneal or intraluminal), per rectal bleeding, vomiting, intestinal obstruction (anastomotic stenosis, adhesions at anastomotic site), wound dehiscence, and incisional hernia [13-15].

### **Aim & Objectives**

The study was carried out with an aim to study the complication profile of stoma closure cases. To find out the proportion of various complications of stoma closure cases and determine the association of various factors associated with complications of stoma closure cases.

### **MATERIALS & METHODS**

This hospital based descriptive type of observational study was conducted in department of

general surgery, SMS Medical College Jaipur from November 2016 to October 2017 on 150 stoma closure cases.

All patients admitted in hospital for reversal and with American society of Anesthesiologist (ASA) physical status grade 1 & 2 were included in study.

Patient with ASA grade 3 or more, HIV and immunosuppressed patients, patients with severe systemic organ dysfunction (diabetes, renal, cardiac

disease), age <12 years & >70 years were excluded from the study.

**OBSERVATION & DISCUSSION**

Various Indication of stoma creation is summarized in Table no. 1 about 57.3% were performed for enteric perforation which was most common indication. Other common indications were Appendectomy with faecal fistula, anterior resection, Postoperative adhesions, Gangrenous caecum, Hartmans procedure, Sigmoid Volvolus. Also seen in various studies done by Turnbull *et al.* [13], Alexander *et al.* [14], Hulten *et al.* [15,17].

**Table-1: Indication of stoma creation**

S.no	Indications of stoma creation	Frequency	Percentage
1.	Anterior resection	5	3.5
2.	Appendectomy with faecal fistula	7	4.7
3.	Caecal perforation	2	1.3
4.	Colonic perforation	3	2.0
5.	Colonic transection with faecal fistula	1	0.7
6.	Enteric perforation	86	57.3
7.	Gangrenous Caecum	4	2.7
8.	Gangrenous gut with BTA	1	0.7
9.	Gunshot injury	3	2.0
10.	Hartmann’s procedure	4	2.7
11.	Ileoileal Resection Anastomosis	1	0.7
12.	Inflammed Meckel’s Diverticulum	1	0.7
13.	Left Hemicolectomy	1	0.7
14.	Liver & Appendicular abscess with pyoperitoneum	1	0.7
15.	Multiple stricture	3	2.0
16.	Pelvic GIST	1	0.7
17.	Post-operative Adhesion	5	3.5
18.	Rectosigmoid mass	3	2.0
19.	Rectovaginal fistula	2	1.3
20.	RTA BTA with posterior anal wall perforation	1	0.7
21.	RTA BTA with transverse colon perforation	2	1.3
22.	SAIO	2	1.3
23.	Sigmoid Volvolus	4	2.7
24.	Sigmoid Perforation	1	0.7
25.	Sigmoid volvulus with colorectal anastomosis	1	0.7
26.	Stricture at ICJ	1	0.7
27.	Transverse colon perforation	1	0.7
28.	Tubercular perforation	2	1.3
29.	Ulcerative colitis	1	0.7
30.	Total	150	100.0

As shown in Figure no 1. About 88.7% of ileostomy closure type of stoma made. Followed by Colostomy closure in 7.3% and ileoileal R/A stoma in 3.3%. Similar studies done by Hulten L *et al.* [15,17,20], Fasth *et al.* [15], Parks *et al.* [18], Goligher *et al.*[19].

Out of all wound infection 15 patients resolved by antibiotics and dressings; while 6 wound infections needed debridement and one died. Patients with features of paralytic ileus (25 cases) resolved conservatively.

26 stomas were reversed in 6 weeks, one hundred six in between 6 – 12 weeks and 23 were reversed after 12 weeks. The causes for delayed

reversal included general fitness for a second operation in 13 patients, 8 patients were lost to follow – up initially and presented late to hospital and 2 patients were on anti – tubercular therapy and reversal was done only after the completion of the course.

123 stomas were reversed under general anaesthesia and 27 under spinal anaesthesia. All stomas were reversed through the same stomal wound. Distal loopogram was done in 121 patients to check the patency of distal bowel. Resection of a portion of the proximal and distal loops before anastomosis was done in five patients, freshening of edges in 116 and ileo – colic anastomosis in ten patients. Anastomosis in single layer was done in all the patients. Primary closure of the skin was done in all patients.

As shown in Figure no. 2 Out of the 150 patients 13 had significant complications. 7 patients had

signs of intestinal obstruction out of which 2 were reported, 25 patients developed signs of paralytic ileus which was managed conservatively and 15 had signs of wound infection, which resolved with dressings and antibiotic cover, out of 6 anastomosis leak reported and 2 managed conservatively, 1 case of enterocutaneous fistula reported was reoperated and out of 5 hernia cases 3 were reported for management and 2 patients failed to consent. Similar studies done by Carlsen *et al.* [21], Fauno *et al.* [22], Saha *et al.* [23].

As shown in Table no.2 major complications like vomiting, abdominal distension and ileus were seen in stoma closure procedure and managed conservatively .Similar studies done by Carlsen *et al.* [21], Fauno *et al.* [22], Saha *et al.* [23], Chow *et al.* [24], Williams *et al.* [25], D’Haenick *et al.* [26], Mansfield *et al.* [27], Rathnayake *et al.* [28], Van de Pavoordt *et al.*[29].

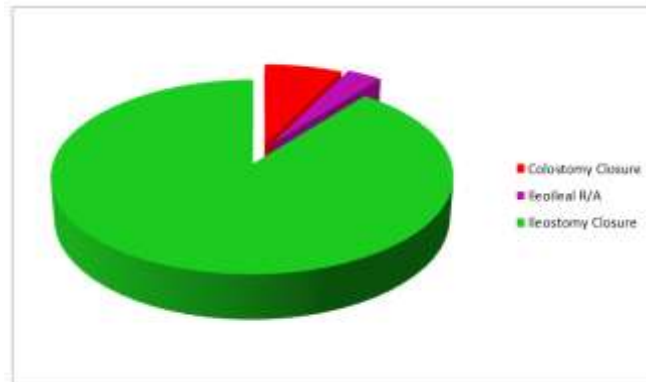


Fig-1: Type of Stomas

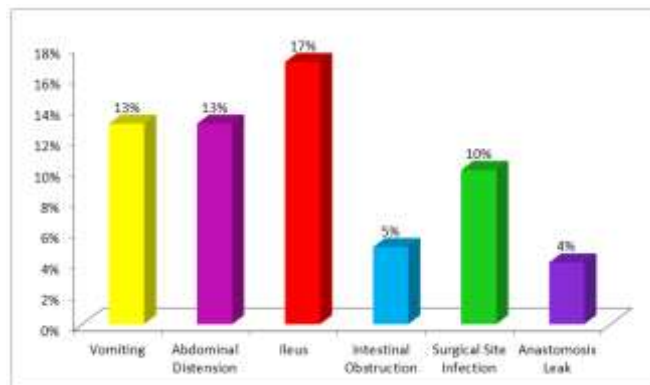


Fig-2: Complications seen After Stoma Closure

Table-2: Percentage of Patient with complications reported

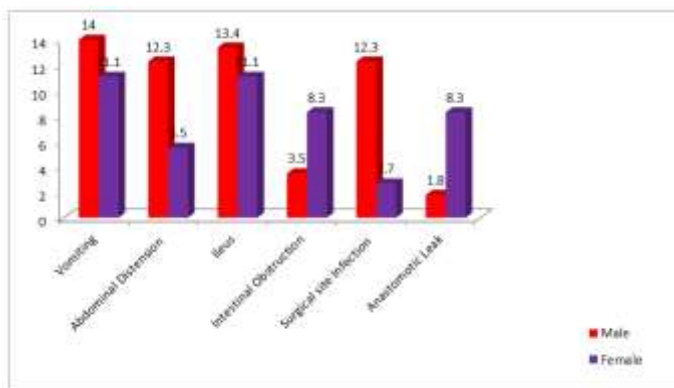
S.no	Complication	Ileostomy Closure %	Colostomy Closure %	Ileo – Ileal R/A%
1.	Vomiting	18.1	11.2	20
2.	Abdominal Distension	10.5	9	20
3.	Ileus	13	9	20
4.	Intestinal Obstruction	3.7	9	0
5.	Surgical site Infection	9.7	0	20
6.	Anastomotic Leak	3	9	0
7.	Enterocutaneous Fistula	0.7	0	0
8.	Per Rectal Bleeding	1.5	0	0

As shown in Table no.3 maximum complications were seen in age group 31 – 40 years Vomiting followed by surgical site infection. In 21- 30 years age group ileus was most common complication followed by surgical site infection. In young patients, 11-20 year age group surgical site infection was

common. In elderly patients vomiting, abdominal distension, intestinal obstruction, surgical site infection were seen. Similar studies done by D’Haenick [26], Mansfield *et al.* [27], Rathnayake *et al.* [28], Van de Pavoordt [29].

**Table-3: Association of various complications with different Age Group**

S.no	Complications	11 – 20 (years)	21 - 30	31 –40	41 –50	51 –60	61 -70
1.	Vomiting	3	4	11	0	1	1
2.	Abdominal Distension	1	4	6	1	3	1
3.	Ileus	2	6	3	1	3	0
4.	Intestinal Obstruction	2	1	3	0	0	1
5.	Surgical Site Infection	8	6	7	2	1	1
6.	Anastomotic Leak	1	0	3	1	0	0
7.	Enterocutaneous Fistula	0	0	0	0	1	0
8.	Hernia	1	2	1	0	1	0
9.	Per Rectal Bleeding	0	0	0	1	1	0



**Fig-3: Association of Complications with Sex**

As shown in figure no.3 vomiting, abdominal distension, ileus was common complication seen in patients irrespective of sex.

There is no recognized optimal timing for reversal of temporary ileostomies. However, most surgeons would advocate early reversal of ileostomies in medically fit and willing patients. The vast majority of patients experience an overall improvement in quality of life, physical function and social function following stoma reversal. Patient’s general medical fitness, which includes age and co – morbidity, may worsen after major surgery and is important in planning any further surgical procedures. A further factor is the patient’s experience of the primary procedure, particularly if they suffered any post – operative complications. In the present study, 84% of stomas were reversed within 12 weeks. There were no significant differences in outcome among early or delayed closure; although some authors have mentioned increasing the delay from creation to reversal may result in fewer complications while others argue that early reversal is feasible.

A routine contrast study is practiced in our study. Among the 150 patients, distal logogram was practiced in 80.99% to check the patency of the distal bowel. The loopogram revealed contrast passing normally up to the rectum. In patients with an ileostomy, with a smooth post – operative course, a radiological examination of the anastomosis prior to ileostomy reversal appears unnecessary. Routine gastrograffin enema in absence of a clinical suspicion of anastomotic failure would appear to be of little value.

Traditionally, the stoma is reversed under general anaesthesia. But with careful patient selection, preparation and a gentle and meticulous surgical technique, reversal of loop ileostomy can be achieved under spinal anaesthesia. In present study, 82% were reversed under general anaesthesia and 18% under spinal anaesthesia. Patients started feeding on the first to third postoperative day. Analgesia requirements postoperatively were similar in both the groups. No complications occurred due to the anaesthetic technique.

All stomas were reversed through the same stomal wound. The postoperative results regarding analgesia, feeding, complications and total days of hospitalization were similar in both the groups. The operative procedure was quicker with minimal dissection because of approaching through the stomal wound.

Resection and anastomosis was done in 3.3% of patients, enterotomy suture in 90% and ileo – colic anastomosis in 6.6%. Anastomosis in a single layer was done in all patients. Postoperative obstruction has been recorded with higher frequency in enterotomy suture compared with resection and anastomosis; or stapled anastomosis and there was no difference in anastomotic leaks between the reversal techniques [10-12]. In this series 4 cases of obstruction required surgical intervention and 5 cases of anastomotic leakage were found.

Prospective comparison between primary closure and delayed primary closure of the wound has unexpectedly shown less wound infection in primary closure [25]. All of the 150 stomas were closed by primary closure and wound infection was reported to be 17%.

## CONCLUSION

The present study confirms that paralytic ileus and vomiting, wound infection is major morbidity with very low percentage of serious complications associated with stoma creation and reversal. Our study, consisting of 150 patients, did not find any difference in the stoma formation, timing of reversal (Although the interval between stoma construction and closure has substantial impact on social and economic status.), anesthesia used, and method of reversal but a significant association was found to be with indication of the cases, hygiene, surgeon experience and nutritional status [Malnutrition, anaemia, hypoalbuminemia and Obesity].

We therefore conclude that temporary stoma reversal can be done safely at an earlier date, with minimal requirement of special anesthesia and minimal access to the abdomen, and that early discharge is safe without expecting serious complications and readmissions.

## REFERENCES

1. Gooszen AW, Geelkerken RH, Hermans J, Lagaay MB, Gooszen HG. Temporary decompression after colorectal surgery: randomized comparison of loop ileostomy and loop colostomy. *British journal of surgery*. 1998 Jan 1;85(1):76-9.
2. Machado M, Hallböök O, Goldman S, Nyström PO, Järhult J, Sjö Dahl R. Defunctioning stoma in low anterior resection with colonic pouch for rectal cancer. *Diseases of the colon & rectum*. 2002 Jul 1;45(7):940-5.
3. Caricato M, Ausania F, Ripetti V, Bartolozzi F, Campoli G, Coppola R. Retrospective analysis of long-term defunctioning stoma complications after colorectal surgery. *Colorectal Disease*. 2007 Jul 1;9(6):559-61.
4. Harris DA, Egbeare D, Jones S, Benjamin H, Woodward A, Foster ME. Complications and mortality following stoma formation. *Annals of the Royal College of Surgeons of England*. 2005 Nov;87(6):427.
5. Tilney HS, Sains PS, Lovegrove RE, Reese GE, Heriot AG, Tekkis PP. Comparison of outcomes following ileostomy versus colostomy for defunctioning colorectal anastomoses. *World journal of surgery*. 2007 May 1;31(5):1143-52.
6. Den Dulk M, Smit M, Peeters KC, Kranenburg EM, Rutten HJ, Wiggers T, Putter H, van de Velde CJ, cooperative investigators of the Dutch Colorectal Cancer Group. A multivariate analysis of limiting factors for stoma reversal in patients with rectal cancer entered into the total mesorectal excision (TME) trial: a retrospective study. *The lancet oncology*. 2007 Apr 1;8(4):297-303.
7. Edwards DP, Leppington-Clarke A, Sexton R, Heald RJ, Moran BJ. Stoma-related complications are more frequent after transverse colostomy than loop ileostomy: a prospective randomized clinical trial. *BJS*. 2001 Mar 1;88(3):360-3.
8. Gooszen AW, Geelkerken RH, Hermans J, Lagaay MB, Gooszen HG. Quality of life with a temporary stoma. *Diseases of the Colon & Rectum*. 2000 May 1;43(5):650-5.
9. Fasth S, Hulten L, Palselius I. Loop ileostomy--an attractive alternative to a temporary transverse colostomy. *Acta Chirurgica Scandinavica*. 1980;146(3):203-7.
10. Bain IM, Patel R, Keighley MR. Comparison of sutured and stapled closure of loop ileostomy after restorative proctocolectomy. *Annals of the Royal College of Surgeons of England*. 1996 Nov;78(6):555.
11. Hasegawa H, Radley S, Morton DG, Keighley MR. Stapled versus sutured closure of loop ileostomy: a randomized controlled trial. *Annals of surgery*. 2000 Feb;231(2):202.
12. Hull TL, Kobe I, Fazio VW. Comparison of handsewn with stapled loop ileostomy closures. *Diseases of the colon & rectum*. 1996 Oct 1;39(10):1086-9.
13. Turnbull RB. The surgical approach to the treatment of inflammatory bowel disease: a personal view of techniques and prognosis. *Inflammatory bowel disease*. Lea & Febiger, Philadelphia. 1975;338.
14. Alexander-Williams J. Loop ileostomy and colostomy for faecal diversion. *Annals of the Royal College of Surgeons of England*. 1974 Mar;54(3):141.
15. Hulten L, Palselius I: Ett nytt förband för enterostomioperade. *Lakartidningen* 77:2196,1980.

16. Fasth S, Hulten L, Palselius I. Loop ileostomy--an attractive alternative to a temporary transverse colostomy. *Acta Chirurgica Scandinavica*. 1980;146(3):203-7.
17. Parks AG, Nicholls R. Proctocolectomy without ileostomy for ulcerative colitis. *Br Med J*. 1978 Jul 8;2(6130):85-8.
18. Goligher JC, Duthie HL, Nixon HH. *Surgery of the anus, rectum and colon*. Bailliere Tindall; 1980.
19. Hultén L, Fasth S. Loop ileostomy for protection of the newly constructed ileostomy reservoir. *British Journal of Surgery*. 1981 Jan 1;68(1):11-3.
20. Carlsen, Erik and Anstein. "Loop ileostomy : technical aspects and complications ." *European Journal of surgery* 165.2 (2003) 140 – 3.
21. Faun L, Rasmussen C, Sloth KK. Low complication rate after stoma closure. *Colorectal disease*, 14:8 (2012) 499 – 505.
22. Saha AK, Tapping CR. "Morbidity and mortality after stoma closure of loop ileostomy." *Colorectal Disease*, 11:8 (2009):866 – 871.
23. Chow, Andre, Henry S. "The morbidity surrounding reversal of refunctioning ileostomies: a systematic review of 48 studies including 6107 cases." *International J of Colorectal Disease*. 24:6(2009):711 – 723.
24. Williams LA, Sagar PM. "The outcome of loop ileostomy closure: a prospective study." *Colorectal disease* .10:5(2007): 460 – 464.
25. D'Haeninck, Wolthius AM. "Morbidity after closure of a defunctioning loop ileostomy." *Acta Chirugica Belgica*111,no. 3 (2011):136.
26. Mansfield SD, Jensen C. "Complications of loop ileostomy closure: a retrospective cohort analysis of 123 patients." *World J of Surgery*.32:9 (2008):2101 – 6.
27. Rathanayke M, Kumarage SK. "Complications of loop ileostomy and ileostomy closure and their implications for extended enterostomal therapy: a prospective clinical study." *International J of nursing studies* 45:8(2008): 1118.
28. Van de Pavoordt, Fazio VW. "The outcome of loop ileostomy closure in 293 cases." *Int J of Colorectal Diseases*. 2:4(1987):214 – 217.