

## Original Research Article

## Histomorphological and anatomical analysis of primary extra nodal non-Hodgkin lymphoma – ten years study from a tertiary cancer centre in South India

Suma Mysore Narayana<sup>1</sup>, Chennagiri Premalata<sup>2</sup>, Usha Amirtham<sup>3</sup>, Geetha Kurlekar<sup>4</sup>, Rekha V Kumar<sup>5</sup>

<sup>1</sup>Assistant professor of Pathology, Kidwai Memorial Institute of oncology, Karnataka

<sup>2</sup>Professor of Pathology, Kidwai Memorial Institute of oncology, Karnataka

<sup>3</sup>Assistant professor of Pathology, Kidwai Memorial Institute of oncology, Karnataka

<sup>4</sup>Former Resident DNB Pathology, Kidwai Memorial Institute of oncology, Karnataka & Presently working as Pathologist, Kempston, Bedfordshire, UK

<sup>5</sup>Professor of Pathology, Kidwai Memorial Institute of oncology, Karnataka

**\*Corresponding author**

Suma Mysore Narayana

Email: [mnssuma19@gmail.com](mailto:mnssuma19@gmail.com)

**Abstract:** A substantial percentage of non-Hodgkin lymphomas (NHL) arise from tissue other than lymph nodes and even from sites which normally contain no lymphoid tissue. These forms are referred to as primary extranodal lymphomas (pENL). From January 2006 to December 2015, a total number of 1529 cases of NHL diagnosed definitely with lymphoma were included. Clinical information including demographics (age, gender) and initial site of involvement was collected. Out of 1529 cases 335 cases were of extranodal origin. This study was undertaken to ascertain the prevalence, anatomical distribution, and histological subtypes of extranodal non-Hodgkin lymphoma (NHL). This is one of the largest data from a single institution from a tertiary referral hospital in Southern India. Extranodal lymphomas constituted 335/1529 (21.9%) of all NHL. These included 209 males and 126 females (M: F= 1.65:1) and peak incidence was during the 4th to 5th decade of life. 296/335 (88.5%) of pENL had B immunophenotype whereas T cell phenotype was observed in only 39/335 patients (11.5%). GIT was the most common site of extranodal lymphomas in our study constituting 32% followed by head and neck 27.5%, CNS 8%, bone 7.5%, skin 7%, mediastinum 5%, testis 4%, soft tissue 3.8%, breast 1.49% and ovary 1%. The least common sites being kidney, urinary bladder, lung/pleura, primary liver and primary spleen. Diffuse large B-cell lymphoma, not otherwise specified (DLBCL) was the most common histological type observed in 172/286 (60%), followed by extranodal marginal zone lymphoma of MALT type 43/286 (15%). The most common histological subtype in children (age<18) was Burkitt lymphoma 20/49(41%) followed by DLBCL 10/49(20%). In adults stomach was the commonest site with DLBCL as frequent histomorphology while in paediatric population it was ileocaecum with Burkitt lymphoma. The incidence of pENL in Indian subcontinent is low compared to data from other parts of the world. Gastrointestinal tract and head and neck were the two most common extra nodal sites observed. The commonest site of involvement was GIT (32%). This is similar to the data from western studies, but differs from the other Indian studies in which head and neck lymphomas and PCNSL were the commonest. Head and neck was the second most common in our study, the reason being Waldeyer's ring and tonsils, were considered as nodal and were excluded from the study. However in many respects, historically they have been included among the extranodal types. Follicular lymphomas were conspicuously very low in the extranodal sites. Compared to published series, no difference was noted in regard to gender predilection and morphology.

**Keywords:** extranodal, non-Hodgkin lymphoma, primary

**INTRODUCTION**

Lymphomas are solid tumors of the immune system. 90% of them are non-Hodgkin lymphoma and remaining 10% are Hodgkin lymphoma. A substantial percentage of non-Hodgkin lymphomas (NHL) arise

from tissue other than lymph nodes and even from sites which normally contain no lymphoid tissue. These forms are referred to as primary extranodal lymphomas (pENL). At least one-fourth of the lymphomas are probably of extranodal origin [1]. Despite this relative

prominence of extranodal presentations, the literature on their incidence and on most of the specific types and sites is scant and often contradictory. Only a minority of the published data have been collected prospectively from population-based registries [2, 3]. Another debate is whether tonsils and Waldeyer's ring should be considered as nodal or extranodal lymphoma sites. In many respects they could be considered of nodal origin, but they have historically been included among the extranodal types [2, 3].

There are great differences in the incidence of extranodal lymphomas among countries: USA 24%, Canada 27%, Israel 36%, Lebanon 44%, Denmark 37%, Holland 41%, Italy 48%, and Hong Kong 29% [1-3, 4]. At least in Western countries the more realistic data are probably those derived from population-based registries [2, 3, 5]. Extra nodal NHLs have been reported to originate from almost every anatomic site of the body such as gastrointestinal tract (most common), head and neck (Waldeyer's ring, nose/paranasal sinuses/nasopharynx, salivary glands, etc.), skin, central nervous system (CNS), bone, testis, thyroid, breast, orbit, and rarely adrenal, pancreas, and the genitourinary tract [6,7, 12-18]. Different criteria have been proposed by various authors in the past, to categorize these entities [8, 9]. As per Dawson criteria, lymphoma is said to be primarily extranodal if 1) absence of palpable superficial lymph nodes on first physical examination; 2) absence of mediastinal lymphadenopathy detected on plain Chest X-ray 3) dominant lesion at extranodal sites 4) involvement of lymph nodes in the vicinity of the primary lesion and 5) white blood cell (WBC) count within normal range.

In addition to the human immunodeficiency virus (HIV) infection, other predisposing factors, such as various viral infections, immunosuppressive treatments or environmental factors, including pesticides and solvents, might explain the increased incidence of extranodal lymphomas [10, 11]. Although numerous papers dealing with primary extranodal lymphomas originating in almost every organ in the body have been published, the literature on primary extranodal lymphoma as a group is limited. This study was undertaken to ascertain the prevalence, anatomical distribution and histological subtypes of extranodal non-Hodgkin lymphoma (NHL) from a tertiary care institute in Southern India. This is one of the largest studies from a single institution from a tertiary referral hospital in Southern India

#### PATIENTS AND METHODS

From January 2006 to December 2015, a total number of 1529 cases of NHL diagnosed definitely with lymphoma were included. Clinical information

including demographics (age, gender) and initial site of involvement was collected. Out of 1529 cases 335 cases were of extranodal origin. The myeloid neoplasms and plasma cell myeloma/plasmacytoma were excluded from the study. Involvement of Waldeyer's ring (tonsil, nasopharynx and base of the tongue) was defined as nodal localizations and was excluded. If the disease was generalized and the dominant lesion was extranodal, it was considered as primary extranodal lymphoma. Slides from routinely processed paraffin embedded tissues stained with haematoxylin and eosin were reviewed. Each tumor was placed into morphological subtypes according to the WHO 2008 classification of haematopoietic and lymphoid neoplasms.

Immunohistochemical (IHC) analyses were performed manually on the paraffin embedded tissue sections by using a panel of monoclonal antibodies (Peroxidase-antiperoxidase method). The basic panel for pENL in our laboratory included CK, LCA, CD20 and CD3. In cases of small cell NHL the panel included CD5, CD23, bcl2, Cyclin D1 and CD10. Antibodies to CD15, CD30, and pax5, EMA, LMP1 and ALK were used to differentiate between PTCL, ALCL and HL. Tdt, BCL6 and Ki67 were added to differentiate between lymphoblastic lymphoma and Burkitt's lymphoma. Additional immunostains that were helpful when differential diagnosis were considered were CD56, CD34, CD117, MPO, Mum1, CD79a, CD68 and CD99. In situ hybridization for EBV encoded RNA (EBER) were performed for nasal NK/T cell lymphoma.

#### RESULTS

A total number of 335 cases of extranodal lymphomas were analysed out of 1529 cases of Non-Hodgkin lymphoma over a period of 10 years. NHL comprised of 10% of all registered malignancies in our hospital, which is a tertiary cancer referral center. Extranodal lymphomas constituted 335/1529 (21.9%) of all NHL. These included 209 males and 126 females (M: F= 1.65:1) and peak incidence was during the 4th to 5th decade of life (age range 3yrs -87 years, mean 48 years). The incidence of pENL is increasing in linear proportion [Figure 2]

286(85%) were adults and 49 (15%) were paediatric population. The ratio of M: F in adults was 171:115(1.5:1) and in paediatric group 38:11(3.5:1). With IHC, 296/335 (88.5%) of pENL had B immunophenotype whereas T cell phenotype was observed in only 39/335 patients (11.5%). Diffuse large B-cell lymphoma, not otherwise specified (DLBCL) was the most common histological type observed in 172/286 (60%), followed by extranodal marginal zone lymphoma of MALT type 43/286 (15%) [Table1].The

most common histological subtype in children was Burkitt lymphoma 20/49(41%) followed by DLBCL 10/49(20%). In adults stomach was the commonest site with DLBCL as frequent histomorphology while in paediatric population it was ileocaecum with Burkitt lymphoma [Figure 3].

GIT was the most common site of extranodal lymphomas in our study constituting 32% followed by head and neck 27.5%, CNS 8%, bone 7.5%, skin 7%, mediastinum 5%, testis 4%, soft tissue 3.8%, breast 1.49% and ovary 1%. The least common sites being kidney, urinary bladder, lung/pleura, primary liver and primary spleen.[Figure 1]. Among GIT Stomach was involved in 50/108(46%) cases with the histology of DLBCL 37(74%) followed by ENMZL 7(14%). The other histological subtypes were B cell lymphoma unclassified (2), MCL (2) and one each of plasmablastic lymphoma and Burkitt lymphoma. 35/108(32%) cases were diagnosed in small intestine with Burkitt morphology in 18/35(51%). Out of 18 cases of Burkitt morphology >70% was seen in paediatric population. The other histological subtypes were DLBCL (10), ENMZL (3), ALCL (1), MCL (1) and PTCL, NOS (1). Large intestine was involved in 18/108(16.6%) of them and the commonest histology was DLBCL. One case of EATL was diagnosed in the jejunum. The rare subsites in GIT included gastro esophageal junction and periampullary region with DLBCL histomorphology [Table 2].

The second most common extranodal site was head and neck region comprising of 57/335(17%). Involvement of Waldeyer's ring (tonsil, nasopharynx and base of tongue) cases was not included in the study. 18/57 (32%) were recorded in the nasal cavity/paranasal sinuses with 67% of them showing DLBCL. Two cases of NK/T cell lymphoma were diagnosed, both of them positive for EBV by EBERISH. There were two cases of plasmablastic lymphoma in the oral cavity with one of them seropositive for HIV. Involvement of ocular adnexa (orbit, conjunctiva, lacrimal gland) was the third common site in head and neck region 35/335(7.16%) and the common type was ENMZL 28/35(80%). CNS was the fourth common site constituting 8% of extra nodal site .DLBCL was the commonest type in central nervous system, 24of 27(89%) cases were DLBCL. Among bone involvement vertebra and femur were the

common subsites (9 and 6 cases) with DLBCL type. Skin was involved in 24/335(6.4%) cases. T cell phenotype was common comprising of 45.8%.7/22 (32%) were anaplastic large cell lymphoma. The other types were DLBCL (6), primary follicular center cell lymphoma (4), MF (2), Sezary syndrome (1), TLBL (2)

Mediastinum comprised of 5% of all pENL and >60% were T lymphoblastic lymphoma. Among male genito urinary system testis is comprised of 3.8% of all pENL and >80% cases were DLBCL. The age group was elderly and all of them were seen in >45years. There were two cases of ENL in urinary bladder one in 4 and ½ year old child with Burkitt morphology and another in an adult with DLBCL. A single case of T lymphoblastic lymphoma was diagnosed in the kidney in a 13yr old male. Among female genital system 4 cases (1%) of pENL was diagnosed in ovary. Two of them in paediatric age group with one each of Burkitt and B lymphoblastic lymphoma were diagnosed. In adults one follicular lymphoma and one DLBCL was documented.

Breast lymphomas comprised of 1.5% of all pENL. 80% were of DLBCL type and I case of follicular lymphoma was documented. Lung was an uncommon site with (0.5%). One case of ENMZL was diagnosed in lung parenchyma and one case of DLBCL was diagnosed in pleura. A single case of primary DLBCL in spleen was diagnosed after complete work up when nodal origin was ruled out. A single case of B cell lymphoma unclassified was diagnosed in the liver after nodal origin was ruled out. There were total of 6 cases (1.79%) of follicular lymphoma and 4 cases of mantle cell lymphoma (1.25%) which were the less common type amongst B cell immunophenotype. Only 61/182 (30%)cases of DLBCL were triaged into GCB and Non GCB type based on Hans' Algorithm using CD10, bcl6 and Mum1. 25/61(40) were of GCB type and 36/61(60) were of NGCB type.

DLBCL- Diffuse large B cell lymphoma, ENMZL- Extra nodal marginal zone lymphoma, TLBL- T Large blastic lymphoma, A:CL- Anaplastic large cell lymphoma, PTCL-NOS-Peripheral T cell lymphoma, not otherwise specified, EATL-Enteropathy associated T cell Lymphoma.

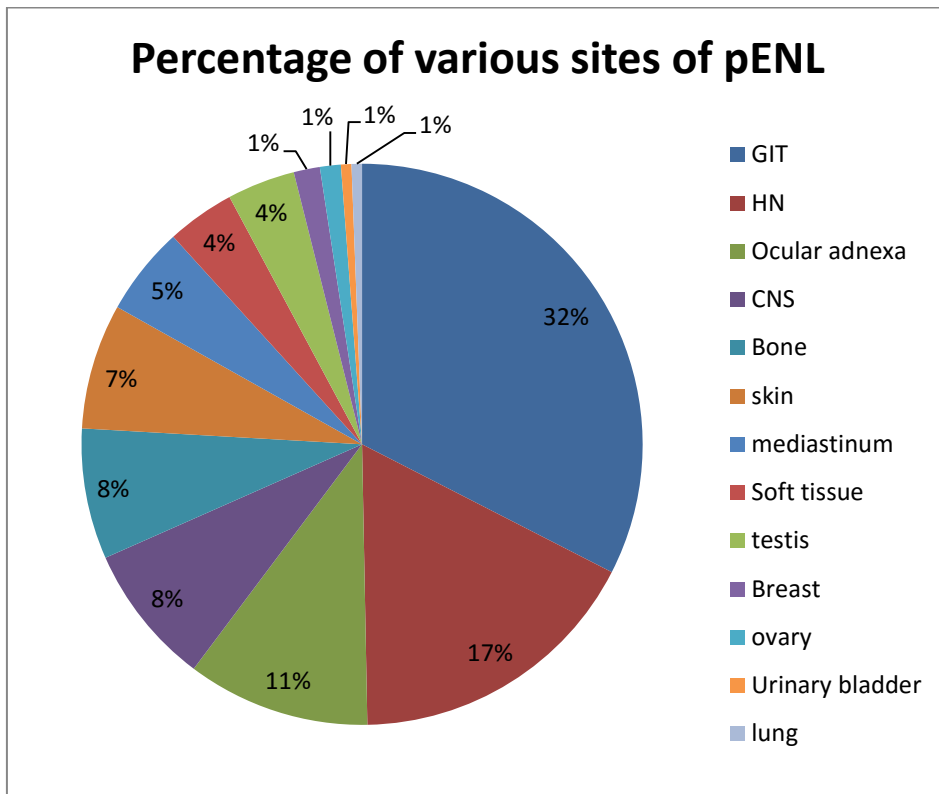


Fig 1: DLBCL- Diffuse large B cell lymphoma, ENMZL- Extra nodal marginal zone lymphoma, TLBLT-Large blastic lymphoma, A:CL- Anaplastic large cell lymphoma, PTCL-NOS-Peripheral T cell lymphoma, not otherwise specified, EATL-Enteropathy associated T cell Lymphoma.

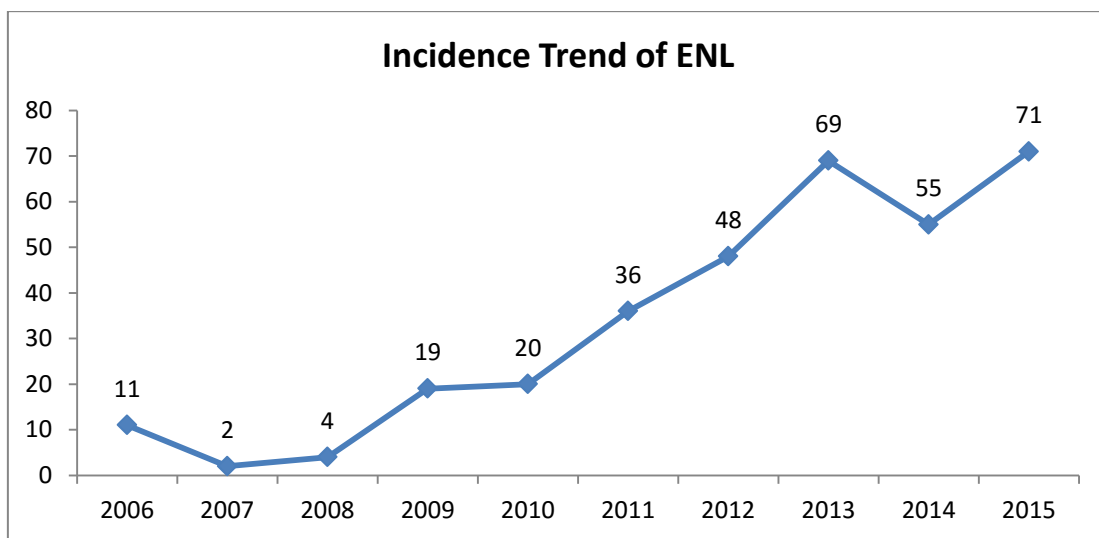
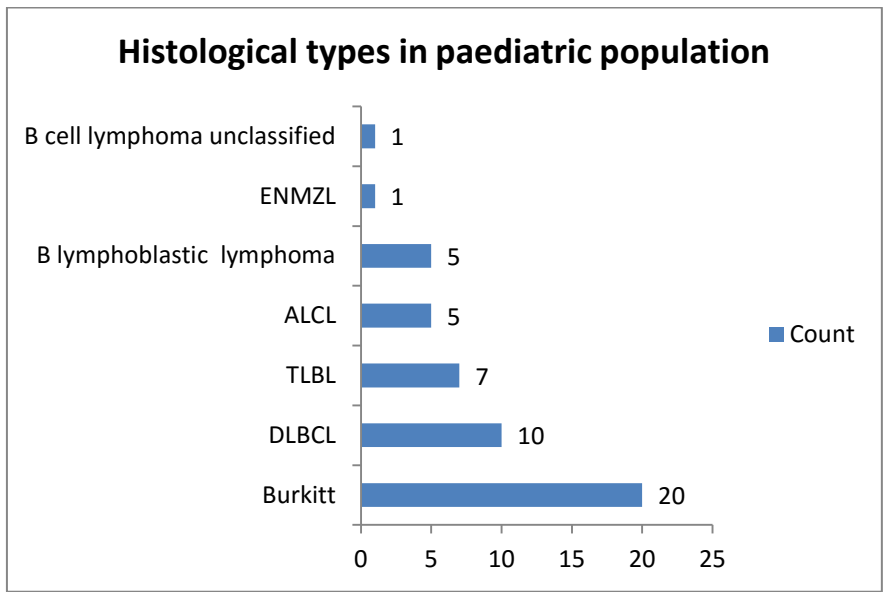
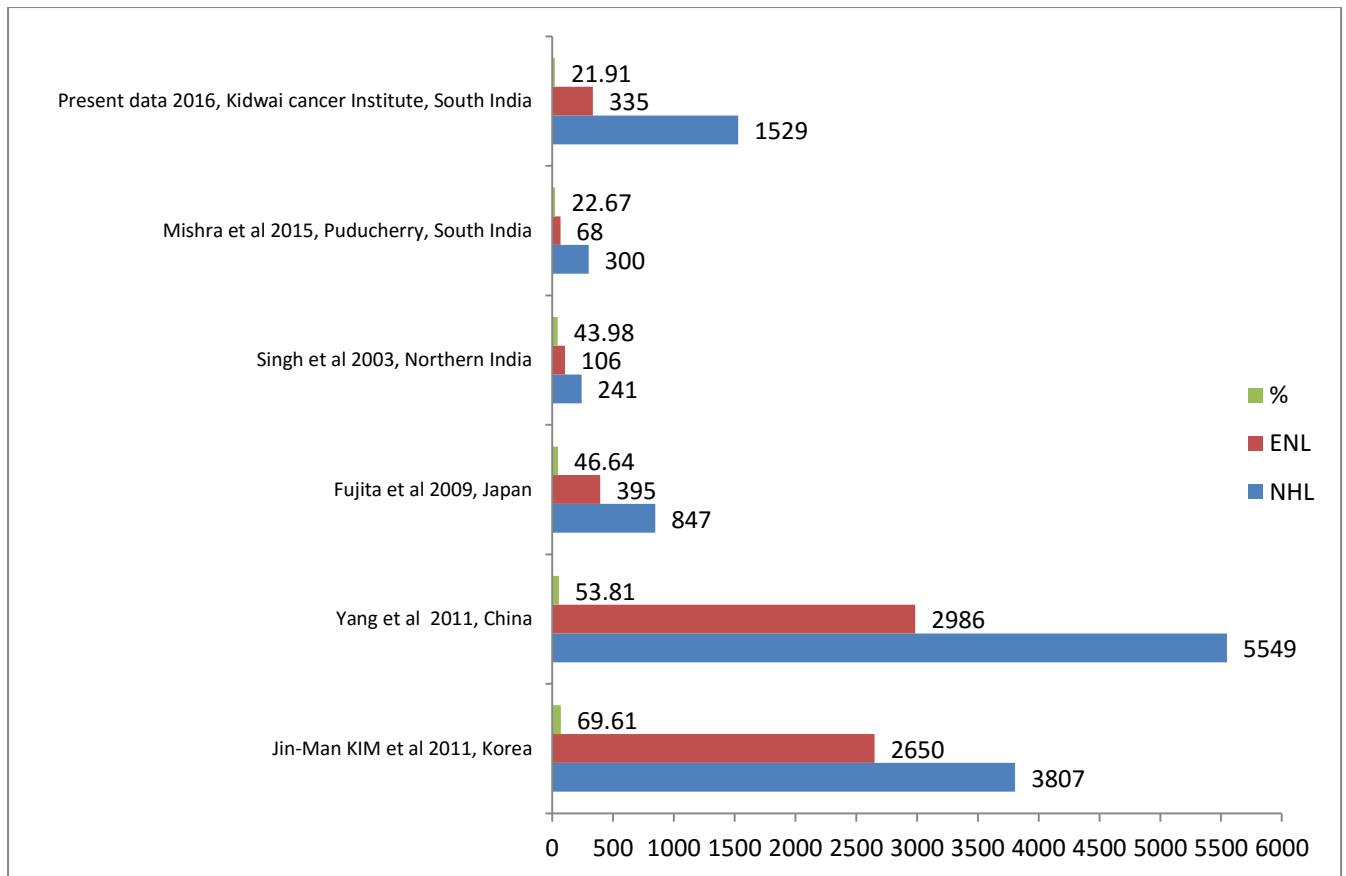


Fig 2: The incidence trend of pENL which shows linear increase



**Fig 3: Histological subtypes in paediatric subgroup**



**Fig 4: Comparison of the percentage of pENL with other studies**

**Table 1: Histological subtypes and the percentage of pENL**

Histological type	Number of cases	Percentage
DLBCL	182	54.33%
ENMZL	44	13.13%
Burkitt	28	8.36%
TLBL	12	3.58%
ALCL	11	3.28%
B cell lymphoma unclassified	10	2.99%
Plasmablastic lymphoma	9	2.69%
B lymphoblastic lymphoma	8	2.39%
PTCL NOS	6	1.79%
Follicular lymphoma	6	1.79%
Mantle cell Lymphoma	4	1.19%
Primary cutaneous follicular centre cell lymphoma	4	1.19%
cutaneous ALCL	4	1.19%
NK /T cell lymphoma	2	0.60%
Mycosis Fungoides	2	0.60%
Sezary syndrome	1	0.30%
Small lymphocytic lymphoma	1	0.30%
Enteropathy ATL	1	0.30%
Total	335	

**Table 2: The histological subtypes at subsites of GIT**

<b>Stomach</b>	<b>50</b>
DLBCL	37
ENMZL	7
B cell lymphoma unclassified	2
MCL	2
Plasmablastic lymphoma	1
Burkitt	1
<b>ileocaecal</b>	<b>30</b>
Burkitt	17
DLBCL	9
ALCL	1
B cell lymphoma unclassified	1
MCL	1
ENMZL	1
<b>colon</b>	<b>17</b>
DLBCL	11
Plasmablastic lymphoma	2
Burkitt	2
MCL	1
ENMZL	1
<b>small intestine</b>	<b>5</b>
ENMZL	2
PTCL NOS	1
Burkitt	1
DLBCL	1
<b>duodenum</b>	<b>1</b>
DLBCL	1
<b>GE junction</b>	<b>1</b>
B cell lymphoma unclassified	1
<b>periampullary</b>	<b>1</b>
DLBCL	1
<b>Jejunum</b>	<b>1</b>
EATL	1
<b>anal</b>	<b>1</b>
Plasmablastic lymphoma	1
<b>ileum</b>	<b>1</b>
DLBCL	1
<b>Total</b>	<b>108</b>

## DISCUSSION

ENL is a heterogeneous group of lymphomas with various pathological subtypes that manifest at different anatomical sites. It accounts for 24-48% of all NHL cases [9]. In our study ENL constituted 21.4% of all NHLs diagnosed over a period of 10 years (2006 to 2015). To avoid a selection bias of cases on applying the strict criteria for the definition of primary extranodal lymphomas, Krol *et al.*; proposed the use of a liberal definition of primary extranodal lymphoma [9]. According to this definition, all those cases who present with lymphoma that apparently originated at an extranodal site can be designated as extranodal, even in the presence of disseminated disease, as long as the extranodal component is dominant.

A previous pioneer study from North India has shown the incidence to be 44% (106 of 241 cases of NHLs over a 3 year period) [6]. However, the incidence of pENL has been shown to be very high in neighbouring Pakistan and Saudi Arabia (up to 50%) Kuwait (45%) Northern Iraq (48.3%) Taiwan (47.2%), Japan (46.6%), Korea (55%) Thailand (58.7%) and China (44.9%-61.4%) [12-18]. Mishra *et al.*; reported 21.6% (68/300) of all NHL in their series [19] similar to our study; however they were liberal and included lymphomas appearing at Waldeyer Ring. When we compare with padhi *et al.*; [20] it is similar to their incidence, and they documented 22% of ENL (excluding Waldeyer ring). The incidence is much less compared to Asian countries and this may be explained by strict inclusion criteria and exclusion of Waldeyer ring from our series [Figure 4]

As illustrated by most of the studies from the developed countries, GIT is the commonest extranodal site of involvement [1, 3]. Our study is in agreement with the various western studies, as majority of our cases involved the GIT as the commonest extranodal site. In a large series by Arora *et al.*; from a single centre in India on GIT lymphomas[49], the stomach was the commonest site, involved in 53.57% of the cases, while the intestines (both large and small) were involved in 43.75% of the cases, but two other studies from India reported small/large intestine as the commonest site [21,22]. Similar to Arora *et al.*; and various studies from UK, Netherlands and Saudi Arabia, in our study the majority of cases of GI lymphomas involved the stomach (46%) while the intestines (both large and small) were involved in 48%. In most studies DLBCL was the commonest histological subtype of primary GIT lymphomas [7, 21]. However Papaxoinis *et al.*; [23] in his series of cases had a higher percentage of ENMZL involving the stomach. Arora *et al.*; recorded 3.27% of T cell lymphomas in their series. We had 3/108(2.7%) pENL

of T cell immunophenotype, the distribution being EATL (1) in jejunum, PTCL, NOS (1) in stomach and ALCL (1) in ileocaecum.

Singh *et al* in his study had head and neck as the commonest extranodal site of presentation, predominantly involving the tonsil, probably due to habit of tobacco chewing or poor dental hygiene. DLBCL was the commonest histological type [6]. In our series, head and neck was the second commonest extranodal site of involvement, however Waldeyer ring involvement was excluded from our study. We encountered two cases of NK/T cell lymphoma, both of them positive for EBV by EBERISH. The important differential diagnosis included malignant melanoma and undifferentiated carcinoma which could be excluded by IHC for S100, HMB45 and CK respectively. EBV sequences can be identified in virtually all cases, strongly suggesting that EBV may play an important role in the pathogenesis of this disease [26, 27].

Primary thyroid lymphoma is uncommon, accounting for only 5% of thyroid neoplasms and less than 2% of extranodal lymphomas [1]. The majority of patients have diffuse large B-cell lymphoma [28]; Elderly women are most often affected, perhaps because of the tendency of this neoplasm to occur against a background of Hashimoto's thyroiditis [29, 30]. All patients were females and age ranged from 55 to 80 yrs. The term primary lymphoma of the ocular adnexa refers to the lymphoma arising in the extra ocular orbital space, involving either the anterior compartment of the orbital cavity (the eyelids, the lacrimal gland and the conjunctiva) or the posterior (retrobulbar) compartment [24]. Orbital lymphoma is considerably more common than intraocular lymphoma (lymphoma of the eye), accounting for about 1%-2% of all lymphomas [4, 25]. ENMZL constituted 80% in the ocular adnexa.

Primary CNS lymphoma (PCNSL) accounts for 1-2% of malignant brain tumours and 2%-4% of all extranodal lymphomas [1, 2, 19]. Padhi *et al.*; from South India recorded central nervous system forming the most common extra nodal site of pENL (20/68, 29.5%), surpassing GIT (17/68, 25%). Mishra *et al.*; from south India recorded 4% in their series [19]. Various multi institutional studies from India in recent past, have addressed the changing trends of PCNSL in regard to incidence, risk factors, and pathophysiology [31-33]. Paul TR in his study reported 56 patients with PCNSLs, all of them were diffuse large B cell lymphomas on histology [33]. In our study DLBCL was the commonest type. Non-Hodgkin lymphoma involving bone constitutes less than 5% of localised extranodal presentations [1, 25, 35]. Qureshi *et al.*; in

his series of 60 cases of primary NHL of bone reported femur as the most common bone involved with the mean age of presentation being 48 years. DLBCL was the commonest histological type [34]. Among bone involvement in our series, vertebra and femur were the common subsites with DLBCL type.

Cutaneous lymphomas can be either of B or T cell type. T cell lymphomas are more common than B cell type in the skin. Primary cutaneous lymphomas represent a group of extranodal lymphomas, accounting for approximately 10% of cases [1]. Primary cutaneous lymphoma is defined as the presence of cutaneous localizations alone, with no nodal or systemic disease over a period of at least six months after the diagnosis [36, 37]. T cell phenotype constituted 12/22 (55%) with cutaneous ALCL as the common morphology. Three of seven ALCL were ALK negative. Falini B *et al* reported that ALK negative ALCL are common in extranodal sites [38]. Primary testicular lymphoma represents 1%-2% of all NHLs [1-3, 4, 25]. This entity is chiefly a disease of the elderly, with 85% of the cases occurring in patients older than 60 [39]. In our analysis the median age of occurrence was 51 yrs.

Primary lymphoma of the breast comprises approximately 2% of all localised extranodal lymphomas [1, 2]. One, which affects young women, is frequently bilateral, often associated with pregnancy, and a high-grade lymphoma [40, 41]. The second group affects older women, presents clinical features identical to epithelial breast cancer. In this second presentation, the most common histology is the diffuse large B-cell type [25, 40, 41]. However in our series breast lymphomas constituted 1.4% of all ENL and DLBCL was the commonest histology. Non-Hodgkin lymphomas of various histologic subtypes, usually diffuse large B-cell lymphoma, have been described in some soft tissues [42]. Intermuscular tissue is the most common localisation but primary skeletal muscle involvement is also well described [43]. In our study soft tissue comprised of 3.8% of extra nodal lymphoma. The presentation was in the skeletal muscle of arm, shoulder, gluteal region and thigh with DLBCL as the common histotype. Primary pulmonary lymphoma is rare, accounting for less than 1% of all extranodal localised disease [38]. Large-cell lymphoma can present primarily in the lung [25]; a second variant is represented by T-cell lymphoma presenting as an angiocentric process within the framework of the lethal midline granuloma. However, the most common histologic type is represented by low grade MALT lymphoma. In our study lung was an uncommon site with (0.5%). One case of ENMZL was diagnosed in lung parenchyma and one case of DLBCL was diagnosed in pleura.

About 20% of nodal non-Hodgkin's lymphomas show evidence of spleen involvement at presentation. However, primary lymphomas of the spleen are quite uncommon [24]. A single case of primary DLBCL in spleen was diagnosed after complete work up when nodal origin was ruled out. Primary lymphoma of the liver is exceedingly rare, with less than 100 cases reported in the literature [44]. A single case of B cell lymphoma unclassified was diagnosed in the liver after nodal origin was ruled out. Follicular lymphomas were conspicuously absent in the extranodal sites, possibly as suggested by Biagi and Seymour, [45] that geographic variation and molecular expression profiling in follicular lymphomas could be a possible explanation. However in our large series they constituted <2% of B cell type. Plasmablastic lymphoma was originally described in the oral cavity in HIV positive individuals. Subsequently it was described at other extranodal sites including testis and lymph nodes [46]. Colomo *et al.*; described that the plasmablastic lymphoma mostly presented at the extranodal sites like rectum and testis [47]. Delecluse HJ *et al.*; noted that plasmablastic lymphoma involving the oral cavity was mainly seen in HIV positive patients [48]. The 9 cases (2.6%) of plasmablastic lymphoma in our study involved rectum(3) stomach (1) Oral cavity(2) nasal cavity(1) and Testis (2)

## CONCLUSION

ENL comprised of 22.4% of all NHL in our study period (2006 to 2015). The commonest site of involvement was GIT (32%). This is similar to the data from western studies, but differs from the other Indian studies in which head and neck lymphomas and PCNSL were the commonest. Head and neck was the second most common in our study. Diffuse large B cell lymphoma was the commonest subtype encountered in all the sites (53.22%). B cell lymphomas were much common than T cell lymphomas. ENL was predominant seen in adults (85%). In paediatric population commonest histology was Burkitt lymphoma. To conclude, the incidence of pENL in Indian subcontinent is low compared to data from other parts of the world. Gastrointestinal tract and head and neck were the two most common extra nodal sites observed. Compared to published series, no difference was noted in regard to gender predilection and morphology.

## REFERENCES

1. Freeman C, Berg JW, Cutler SJ. Occurrence and prognosis of extranodal lymphomas. *Cancer*. 1972 Jan 1; 29(1):252-60.
2. Otter R, Gerrits WB, Sandt MM, Hermans J, Willemze R, Group S. Primary extranodal and nodal non-Hodgkin's lymphoma: A survey of a



- population-based registry. *European Journal of Cancer and Clinical Oncology*. 1989 Aug 31; 25(8):1203-10.
3. d'Amore F, Christensen BE, Brincker H, Pedersen NT, Thorling K, Hastrup J, Pedersen M, Jensen MK, Johansen P, Andersen E, Bach B. Clinicopathological features and prognostic factors in extranodal non-Hodgkin lymphomas. *European Journal of Cancer and Clinical Oncology*. 1991 Oct 1; 27(10):1201-8.
  4. Cavalli F. Extranodal lymphomas. In Magrath IT (ed): *The Non- Hodgkin's Lymphomas*, 2nd edn, London: Arnold 1997: 1007-27.
  5. Morgan G, Vornanen M, Puitinen J, Naukkarinen A, Brincker H, Olsen J, Coeburgh JW, Vrints LW, Clayden D, McNally R, Jack A. Changing trends in the incidence of non-Hodgkin's lymphoma in Europe. *Annals of oncology*. 1997 Jan 1; 8(suppl 2):S49-54.
  6. Singh D, Kumar L, Goyal H, Raina V, Bijlani L, Wadhwa J. Primary extranodal non-Hodgkin's lymphoma in northern India. In *Proc Am Soc Clin Oncol 2003* (Vol. 22, p. 2457).
  7. Al Shemmari SH, Ameen RM, Sajjani KP. Extranodal lymphoma: a comparative study. *Hematology*, 2008; 13: 163-9.
  8. Dawson IM, Cornes JS, Morson BC. Primary malignant lymphoid tumours of the intestinal tract. Report of 37 cases with a study of factors influencing prognosis. *British Journal of Surgery*. 1961 Jul 1; 49(213):80-9.
  9. Krol AD, Le Cessie S, Snijder SA, Kluin-Nelemans JC, Kluin PM, Noordijk EM. Primary extranodal non-Hodgkin's lymphoma (NHL): the impact of alternative definitions tested in the Comprehensive Cancer Centre West population-based NHL registry. *Annals of Oncology*. 2003 Jan 1; 14(1):131-9.
  10. Weisenburger DD. Epidemiology of non-Hodgkin's lymphoma: recent findings regarding an emerging epidemic. *Annals of Oncology*. 1994 Jan 1; 5(suppl 1):S19-24.
  11. Levine Ph, Hoover RN. The emerging epidemic of non-Hodgkin's lymphoma: Current knowledge regarding aetiologic factors. *Cancer Res* 1992; 42 (Suppl): S5425-S5474.
  12. Nagi AH, Al Minawy LU, Naseem NA, Henna SN, Naveed IA. A study of the morphological patterns of extranodal non-Hodgkin lymphoma in Pakistani and Saudi populations. *Biomedica*. 2010 Jul; 26(2):118-23.
  13. Chen WL, Tsai WC, Chao TY, Sheu LF, Chou JM, Kao WY, Chen YC, Ho CL. The clinicopathological analysis of 303 cases with malignant lymphoma classified according to the World Health Organization classification system in a single institute of Taiwan. *Annals of hematology*. 2010 Jun 1; 89(6):553-62.
  14. Temmim L, Baker H, Amanguno H, Madda JP, Sinowatz F. Clinicopathological features of extranodal lymphomas: Kuwait experience. *Oncology*. 2005 Feb 8; 67(5-6):382-9.
  15. Yoon SO, Suh C, Lee DH, Chi HS, Park CJ, Jang SS, Shin HR, Park BH, Huh J. Distribution of lymphoid neoplasms in the Republic of Korea: analysis of 5318 cases according to the World Health Organization classification. *American journal of hematology*. 2010 Oct 1; 85(10):760-4.
  16. Yang QP, Zhang WY, Yu JB, Zhao S, Xu H, Wang WY, Bi CF, Zuo Z, Wang XQ, Huang J, Dai L. Subtype distribution of lymphomas in Southwest China: analysis of 6,382 cases using WHO classification in a single institution. *Diagnostic pathology*. 2011 Aug 22; 6(1):77.
  17. Fujita A, Tomita N, Fujita H, Motohashi K, Hyo R, Yamazaki E, Hattori M, Fujisawa S, Kanamori H, Ogawa K, Motomura S. Features of primary extranodal lymphoma in Kanagawa, a human T-cell leukemia virus type 1 nonendemic area in Japan. *Medical Oncology*. 2009 Mar 1; 26(1):49.
  18. Yaqo RT, Hughson MD, Sulayvani FK, Al-Allawi NA. Malignant lymphoma in northern Iraq: a retrospective analysis of 270 cases according to the World Health Organization classification. *Indian journal of cancer*. 2011 Oct 1; 48(4):446.
  19. Mishra P, Das S, Kar R, Jacob SE, Basu D. Primary extranodal non-Hodgkin lymphoma: A 3-year record-based descriptive study from a tertiary care center in Southern India. *Indian Journal of Pathology and Microbiology*. 2015 Jul 1; 58(3):296.
  20. Padhi S, Paul TR, Challa S, Prayaga AK, Rajappa S, Raghunadharao D, et al. Primary extranodal non Hodgkin lymphoma: A 5 year retrospective analysis. *Asian Pac J Cancer Prev* 2012; 13:4889-95.
  21. Ramesh Chandran R, Hemanth Raj E, Chaturvedi HK. Primary gastrointestinal lymphoma: 30-year experience at the cancer institute, madras, india. *Journal of surgical oncology*. 1995 Sep 1; 60(1):41-9.
  22. Raina V, Sharma A, Vora A, Shukla NK, Deo SV, Dawar R. Primary Non Hodgkin lymphoma chemotherapy alone an effective treatment modality: Experience from a single centre in India. *Indian J Cancer* 2006; 43:30-35
  23. Papaxoinis G, Papageorgiou S, Rontogianni D, Kaloutsis V, Fountzilias G, Pavlidis N, Dimopoulos M, Tsatalas C, Xiros N, Economopoulos T. Primary gastrointestinal non-Hodgkin's lymphoma: a clinicopathologic study of 128 cases in Greece. A Hellenic Cooperative Oncology Group study

- (HeCOG). Leukemia & lymphoma. 2006 Jan 1; 47(10):2140-6.
24. Zucca E, Roggero E, Bertoni F, Conconi A, Cavalli F (1999). Primary extranodal non-Hodgkin's lymphomas. Part 2: Head and neck, central nervous system and other less common sites. *Ann Oncol*, **10**, 1023-33.
25. Sutcliffe SB, Gospodarowicz MK. Clinical features and management of localized extranodal lymphomas. *Haematological oncology*. 1992 Dec 3; 2:189-223.
26. Weiss LM, Arber DA, Stickler JG. Nasal T-cell lymphoma. *Ann Oncol* 1994; 5 (Suppl 1): S39-S42.
27. Weiss LM, Picker LJ, Grogan TM, Warnke RA, Sklar J. Absence of clonal beta and gamma T-cell receptor gene rearrangements in a subset of peripheral T-cell lymphomas. *The American journal of pathology*. 1988 Mar; 130(3):436.
28. Doria R, Jekel JF, Cooper DL. Thyroid lymphoma. The case for combined modality therapy. *Cancer*. 1994 Jan 1; 73(1):200-6.
29. Hyjek E, Isaacson PG. Primary B cell lymphoma of the thyroid and its relationship to Hashimoto's thyroiditis. *Human pathology*. 1988 Nov 1; 19(11):1315-26.
30. Anscombe AM, Wright DH. Primary malignant lymphoma of the thyroid-a tumour of mucosa-associated lymphoid tissue: review of seventy-six cases. *Histopathology*. 1985 Jan 1; 9(1):81-97.
31. Sarkar C, Sharma MC, Deb P, Singh R, Santosh V, Shankar SK. Primary central nervous system lymphoma-A hospital based study of incidence and clinicopathological features from India (1983-2003). *Journal of neuro-oncology*. 2005 Jan 1; 71(2):199-204.
32. Primer BS, Sistemi SS. Primary CNS lymphoma in immunocompetent: A review of literature and our experience from Kashmir. *Turkish neurosurgery*. 2011; 21(1):39-47.
33. Paul TR, Challa S, Tandon A, Panigrahi MK, Purohit AK. Primary central nervous system lymphomas: Indian experience, and review of literature. *Indian journal of cancer*. 2008 Jul 1; 45(3):112.
34. Qureshi A, Ali A, Riaz N, Pervez S. Primary non-hodgkin's lymphoma of bone: experience of a decade. *Indian Journal of Pathology and Microbiology*. 2010 Apr 1; 53(2):267.
35. Baar J, Burkes RL, Bell R, Blackstein ME, Fernandes B, Langer F. Primary non-Hodgkin's lymphoma of bone. A clinicopathologic study. *Cancer*. 1994 Feb 15; 73(4):1194-9.
36. Kerl H, Cerroni L. Primary B-cell lymphoma of the skin. *Ann Oncol* 1997; 8 (Suppl 2): 529-32.
37. Russell-Jones R, Spittle MF. Management of cutaneous lymphoma. In: Lynch DC (ed): *Non-Hodgkin's Lymphomas*. Vol 9 of *Bailliere's Clinical Haematology*. London: Bailliere Tindall 1996; 743-67.
38. Falini B, Pileri S, Zinzani PL, Carbone A, Zagonel V, Wolf-Peeters C, Verhoef G, Menestrina F, Todeschini G, Paulli M, Lazzarino M. ALK+ lymphoma: clinico-pathological findings and outcome. *Blood*. 1999 Apr 15; 93(8):2697-706.
39. Møller MB, d'Amore F, Christensen BE, Danish Lymphoma Study Group. Testicular lymphoma: a population-based study of incidence, clinicopathological correlations and prognosis. *European Journal of Cancer*. 1994 Jan 1; 30(12):1760-4.
40. Bobrow LG, Richards MA, Happerfield LC, Diss TC, Isaacson PG, Lammie GA, Millis RR. Breast lymphomas: a clinicopathologic review. *Human pathology*. 1993 Mar 1; 24(3):274-8.
41. Jeon HJ, Akagi T, Hoshida Y, Hayashi K, Yoshino T, Tanaka T, Ito J, Kamei T, Kawabata K. Primary non-hodgkin malignant lymphoma of the breast: An immunohistochemical study of seven patients and literature review of 152 patients with breast lymphoma in Japan. *Cancer*. 1992 Nov 15; 70(10):2451-9.
42. Lanham GR, Weiss SW, Enzinger FM. Malignant Lymphoma: A Study of 75 Cases Presenting in Soft Tissue. *The American journal of surgical pathology*. 1989 Jan 1; 13(1):1-0.
43. Bertoni FR, Sanna PI, Zucca EM, Roggero EN, Cavalli FR. Primary extranodal lymphoma of skeletal muscles: a report of four cases. *Oncology reports*. 1998 May 1; 5:605-8.
44. Kit Lei KI. Primary non-Hodgkin's lymphoma of the liver. *Leukemia & lymphoma*. 1998 Jan 1; 29(3-4):293-9.
45. Biagi JJ, Seymour JF. Insights into the molecular pathogenesis of follicular lymphoma arising from analysis of geographic variation. *Blood*. 2002 Jun 15; 99(12):4265-75.
46. Castillo JJ, Reagan JL. Plasmablastic lymphoma: a systematic review. *The Scientific World Journal*. 2011; 11:687-96.
47. Colomo L, Loong F, Rives S, Pittaluga S, Martínez A, López-Guillermo A, Ojanguren J, Romagosa V, Jaffe ES, Campo E. Diffuse large B-cell lymphomas with plasmablastic differentiation represent a heterogeneous group of disease entities. *The American journal of surgical pathology*. 2004 Jun 1; 28(6):736-47.
48. Delecluse HJ, Anagnostopoulos I, Dallenbach F, Hummel M, Marafioti T, Schneider U, Huhn D, Schmidt-Westhausen A, Reichart PA, Gross U, Stein H. Plasmablastic lymphomas of the oral cavity: a new entity associated with the human

immunodeficiency virus infection. *Blood*. 1997 Feb 15; 89(4):1413-20.

49. Arora N, Manipadam MT, Pulimood A, Ramakrishna BS, Chacko A, Kurian SS, Nair S. Gastrointestinal lymphomas: pattern of distribution and histological subtypes: 10 years' experience in a tertiary centre in South India. *Indian Journal of Pathology and Microbiology*. 2011 Oct 1; 54(4):712.