

## Case Report

**Leptospiral Neuroretinitis in Pregnancy**

Lai Chan Fhun, Moon Yee Cheong, Mei Fong Chong.

Eye clinic, Department of Ophthalmology, Hospital Raja Perempuan Bainun, 31400 Ipoh, Perak, Malaysia

**\*Corresponding author**

Dr. Fhun Lai Chan

Email: [fhunella@hotmail.com](mailto:fhunella@hotmail.com)

**Abstract:** We report a case of leptospirosis Neuroretinitis in pregnancy. A 25-year-old Malay female, primigravida at 4 weeks of period of amenorrhea (POA) with no underlying co morbidity, she presented with initial complaint of right eye sudden onset blurring of vision, right central scotoma for 4 days. There was history of intermittent fever associated with chills and visiting a jungle area one month prior to presentation. On examination, visual acuity of right eye was 6/60; visual acuity of left eye was 6/6. There was relative afferent papillary defect (RAPD) at the right eye. The anterior segment were normal both eyes. Examination of the right eye fundus showed hyperaemic disc swelling with blurred margin at the right eye. There was also hyperaemic appearance of the left optic. After 4 days admission, noted her fundus showed incomplete macular star at the right eye. Her Leptospiral serology titre was positive. Intravenous ceftazidime was commenced for her. Her vision of right eye improved to 6/12 after 2 months of treatment.

**Keywords:** Neuroretinitis, leptospirosis, pregnancy

**INTRODUCTION:**

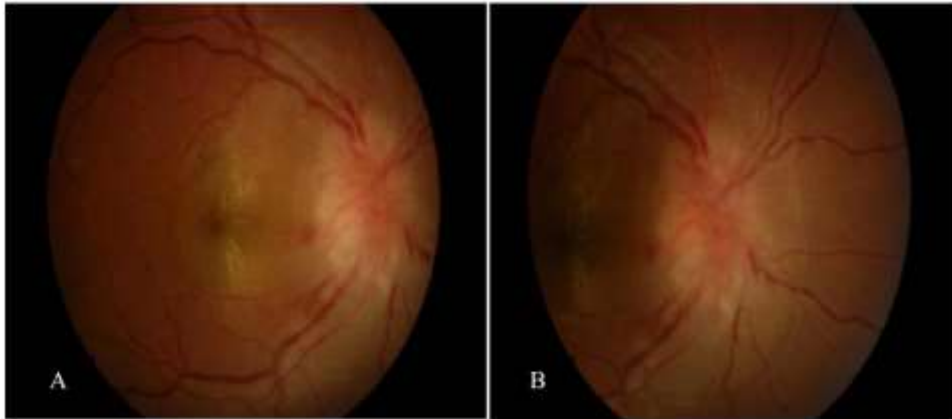
Neuroretinitis is an inflammatory disorder of the optic nerve head characterized by acute, painless visual loss associated with optic disc edema and later formation of lipid deposits that along the outer plexiform layer to form macular star figure [1]. It is associated with a number of specific infectious conditions including tuberculosis, syphilis, mumps, toxoplasmosis, Lyme disease and cat-scratch disease. Ocular leptospirosis is a zoonotic disease caused by spirochetes belonging to the genus *Leptospira* [2, 3]. .

**CASE REPORT**

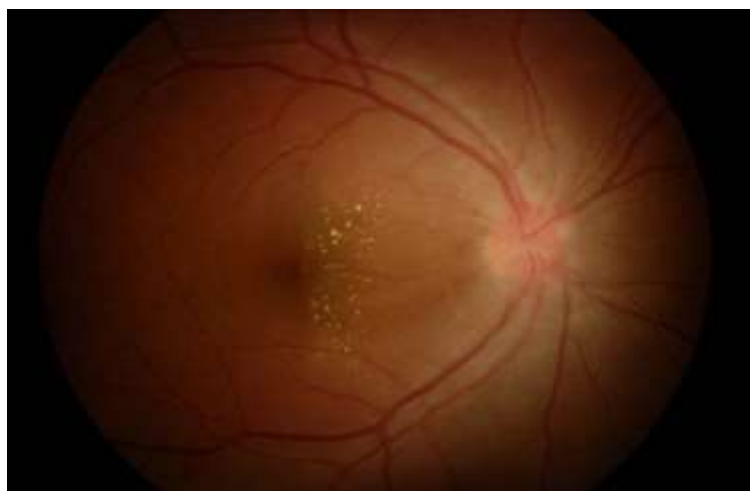A 25-year-old Malay female, primigravida at 4 weeks of period of amenorrhea (POA) with no underlying co morbidity, she presented with initial complaint of right eye sudden onset blurring of vision without ocular pain on eye movement for 4 days. There was right central scotoma and presence of floaters. Otherwise, there was not associated with

metamorphopsia. She also had no history of redness of eye, diplopia and photophobia. Further history revealed of history of intermittent fever associated with chills and history of visiting a jungle area without involving in water spots one month prior to presentation.

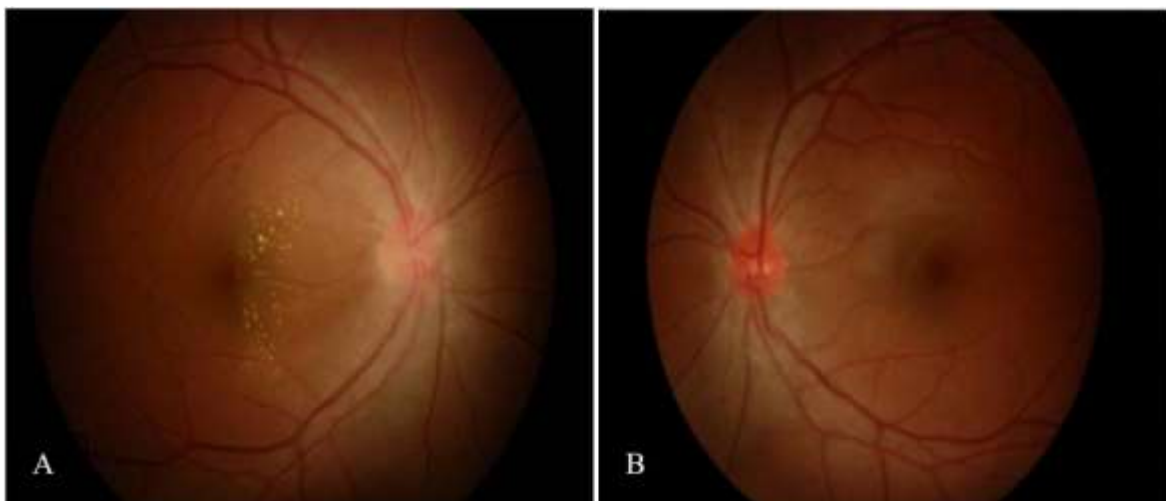
On examination at initial presentation, visual acuity of right eye was 6/60, and not improved by pin hole, visual acuity of left eye was 6/6. There was relative afferent papillary defect (RAPD) at the right eye with red desaturation. The anterior segment were normal both eyes. Examination of the right eye fundus showed hyperaemic disc swelling with blurred margin at the right eye (Figure 1). There was also hyperaemic appearance of the left optic disc (Figure 2). Otherwise, there was no retinitis, Vitritis or vasculitis in both eyes. After 4 days admission, noted her fundus showed incomplete macular star at the right eye. The right optic disc swelling was more prominent (Figure 3).



**Fig 1: (A) Right eye fundus showed progression with newly developed incomplete macular star and more prominent optic disc swelling. (B) Prominent optic disc swelling with peripapillary flame shape haemorrhages.**



**Fig 2: Left eye fundus showed left optic disc was hyperaemic without optic disc swelling**



**Fig 3: Two months after treatment with intravenous antibiotic showed gradual resolution of right optic disc swelling with right optic disc margin appeared more delineated and partial absorption of incomplete macular star (A). The left optic disc appeared less hyperaemic (B)**

Investigation was showed normal full blood count. Erythrocyte sedimentation rate (ESR) was 32 mm per hour, C- reactive protein (CRP) was high at

42.3 and positive Leptospiral serology titre with 1:200 from microscopic agglutination test (MAT). A diagnosis of bilateral neuroretinitis was made.

Intravenous ceftazidime was commenced for her. Patient responded well to intravenous antibiotic without complications and showed resolution of her symptoms and signs. Her vision of right eye improve to 6/12, pinhole 6/9 after 2 months of treatment.

## DISCUSSION

Neuroretinitis presents with sudden vision loss, optic disc swelling and lipid deposits in star shape pattern at macular whether partial or incomplete form [1]. The visual acuity is variable at the initial examination, and cecentral scotoma is the commonest form visual defect. However, central scotoma and accurate visual field defect may also be present [4]. In most of the cases, the optic disc, optic disc swelling is segmental rather than diffuse. And absorption of disc and retinal edema begins after 2 weeks. In most cases, the edema resolves in 6 to 8 weeks. The macula exudates initially progress but stabilize over several weeks and then resolve over several months. Residual macular pigmentary changes may remain in certain group of patients [5]. For our patient, she had history of going to jungle which correlated well with the incubation period and onset of disease manifestation.

Ocular leptospirosis is often under diagnosed because of its protean manifestation, lack of awareness and no availability of laboratory support [2, 3, 6]. Besides, the prolonged symptoms-free period that separates the systemic manifestation from emergence of ocular manifestation often makes the diagnosis difficult [2, 6]. As for this patient, she had systemic symptoms 1 month before developed ocular manifestation. The delay ocular manifestation most likely is due to the immunologic phase of leptospirosis [3].

The treatment of Leptospiral neuroretinitis is systemic antibiotic such as ampicillin, doxycycline, gentamicin, cepheims and macrolides [7-9]. However, this patient is in early pregnancy, the choices of systemic antibiotic of are limited. Early treatment of antibiotic in this patient resulted in excellent visual outcome. Till now, the role of systemic corticosteroid is still controversial in treating neuroretinitis of leptospirosis. There are reports have showed a good response to corticosteroid in neuroretinitis of leptospirosis [4, 8]. In view of our patient was pregnant, we deferred the corticosteroid therapy. In a small subgroup of patients, visual recovery is poor due to viral vasculitis with subsequent obliteration of preliminary arterioles leading to disc infarction [10]. Hence, early diagnosis and treatment is very important to prevent complication which can lead to permanent visual loss.

## CONCLUSIONS

Neuroretinitis secondary to leptospirosis is rare. Management of leptospiral neuroretinitis with

prompt initiation of systemic antibiotic improves the visual outcome and hasten the visual recovery. Further randomized studies are required to consolidate those findings.

## REFERENCES:

1. Ghauri RR, Lee AG. Optic disk edema with a macular star. Survey of ophthalmology. 1998 Dec 31;43(3):270-4.
2. Rathinam SR. Ocular manifestations of leptospirosis. Journal of postgraduate medicine. 2005 Jul 1;51(3):189.
3. Rathinam SR. Ocular leptospirosis. Current opinion in ophthalmology. 2002 Dec 1;13(6):381-6.
4. Narayan SK, Kaliaperumal S, Srinivasan R. Neuroretinitis, a great mimicker. Annals of Indian Academy of Neurology. 2008 Apr 1;11(2):109.
5. Matsuo T, Yamaoka A, Shiraga F, Takasu I, Okanouchi T, Nagayama M, Baba T, Hayashi M, Sarada K. Clinical and angiographic characteristics of retinal manifestations in cat scratch disease. Japanese journal of ophthalmology. 2000 Apr 30; 44(2):182-6.
6. Viswanathan S, Ramkumar VA, Sanjana E, Sampath R. A case of leptospirosis with ocular manifestations. Sri ramachandra. 2007 Nov:57.
7. Basumatary LJ, Das S, Das M, Goswami M, Kayal AK. Leptospirosis presenting as neuroretinitis. Journal of neurosciences in rural practice. 2012 May 1; 3(2):224.
8. Ghosh S, Das R, Saha M, Das D. Neuroretinitis as an unusual manifestation of leptospirosis: A case report. Journal of Clinical & Experimental Ophthalmology. 2012 Feb 8;2011.
9. Kobayashi Y. Clinical observation and treatment of leptospirosis. Journal of infection and chemotherapy. 2001 Jun 1;7(2):59-68.
10. Sundaram SV, Purvin VA, Kawasaki A. Recurrent idiopathic neuroretinitis: natural history and effect of treatment. Clinical & experimental ophthalmology. 2010 Aug 1;38(6):591-6.