

Original Research Article

## Endometrial Hyperplasia: A 3 - Years Study At a Rural Based Hospital

Dr. Mohd. Jafar Memon<sup>1</sup>, Dr. Yashita Gupta<sup>2</sup><sup>1</sup>Assistant Professor, Department of Pathology, Pt. JNM Medical College, Raipur (C.G)<sup>2</sup>Senior Resident, Department of Pathology and Lab Medicine, AIIMS, Raipur (C.G)

### \*Corresponding author

Dr. Yashita Gupta

Email: [yashigupta@gmail.com](mailto:yashigupta@gmail.com)

**Abstract:** Endometrial hyperplasia is an important precursor lesion of endometrioid carcinoma, the most common type of endometrial carcinoma. We studied 480 cases including endometrial curetting, dilatation and curettage and hysterectomy specimen done mainly for the complaint of abnormal uterine bleeding. We found endometrial hyperplasia associated with obesity, diabetes, nulliparity, anovulatory cycles and hormonal therapy. Increased incidence of complex hyperplasia was noted as compared to other studies performed in the past. Due to limitations of rural setting the follow-up endometrial biopsy was available in only 85 patients. We emphasize upon more studies on endometrial biopsies in women living in rural settings who have less access to proper medical aids and knowledge of hormonal therapies, in order to have a comprehensive data on the incidence of endometrial disorders.

**Keywords:** Endometrial hyperplasia, abnormal uterine bleeding, complex hyperplasia, rural setting

### INTRODUCTION

As per 1994 WHO classification scheme, endometrial hyperplasia based on both architectural and cytological abnormalities was classified into 4 categories:

1. Simple hyperplasia (SH),
2. Simple hyperplasia with atypia (SHA),
3. Complex hyperplasia (CH), and
4. Complex hyperplasia with atypia (CHA).

The updated classification scheme for endometrial hyperplasia was introduced by the World Health Organization (WHO) in 2014 as 2 categories:

1. Benign endometrial hyperplasia (BEH), and
2. Atypical endometrial hyperplasia (AEH)/ Endometrioid intraepithelial neoplasia (EIN)

The defining feature of the 2014 classification scheme is the presence (AEH/EIN) or absence (BEH) of cytological atypia superimposed on a background of endometrial hyperplasia [1].

We followed the 1994 classification for the evaluation of endometrial biopsies in this study. The purpose of this study is to evaluate the incidence of various endometrial disorders presenting mainly as abnormal uterine bleeding being an important factor for social, psychological and physical well-being of any

female patient. The clinical correlations were made to find the risk factors associated with these disorders. This study was solely performed to evaluate the endometrial disorders in rural settings where due to lack of awareness and social stigma patients present late to the Gynecologists with their complaints.

### MATERIAL AND METHODS

The retrospective study was conducted from January 2013 to 2015 December over a period of 3 years. Consent was taken from the patients and their attenders for the study. All the patients attending the Gynecology OPD with the complaints of abnormal uterine bleeding and who underwent endometrial curetting, dilatation and curettage and hysterectomy were included. Proforma was used to record the relevant and detailed clinical history from patients.

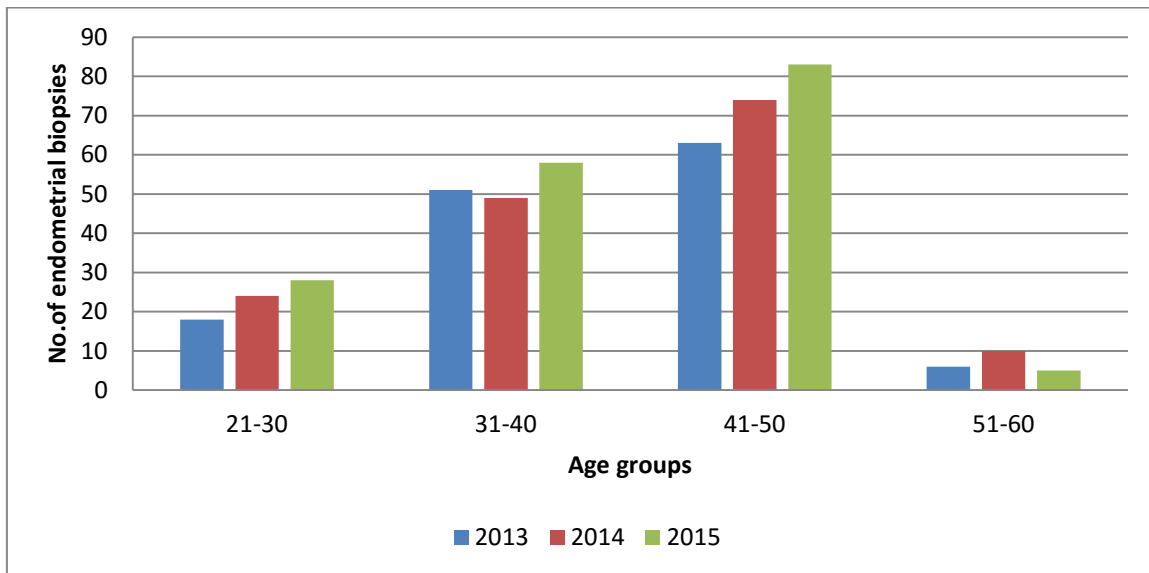
The specimens were received in 10% formalin. After adequate fixation depending upon the type of procedure, tissue processing and H&E staining was performed. Slides were reviewed by two pathologists independently to reduce the chances of biased report. Ethical approval was taken from the hospital ethical committee.

**RESULTS**

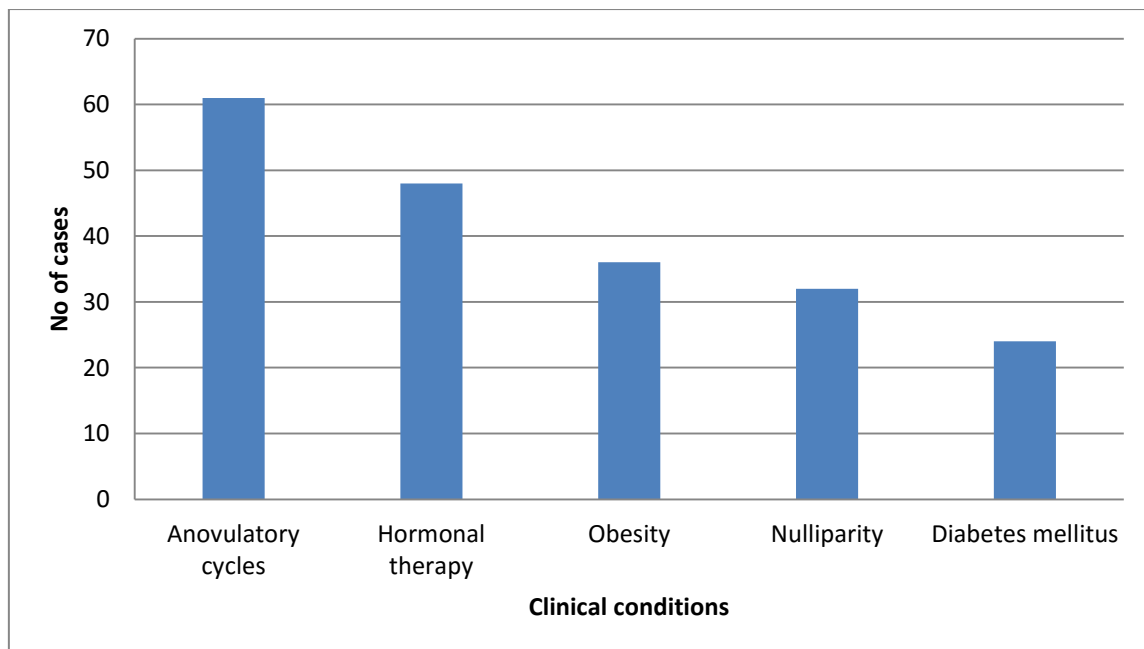
Total 480 cases of endometrial biopsies were analysed. Out of total, 201 cases of endometrial hyperplasia were reported. As per age, endometrial biopsies broadly show maximum distribution in 3rd to 4th decade. [Figure 1].

Endometrial hyperplasia cases were reported as per 1994 WHO classification. Maximum cases reported were of simple hyperplasia. Rest endometrial biopsy cases were reported predominantly as phase changes, hormonal effects, polyps and atrophy. [Figure 3]

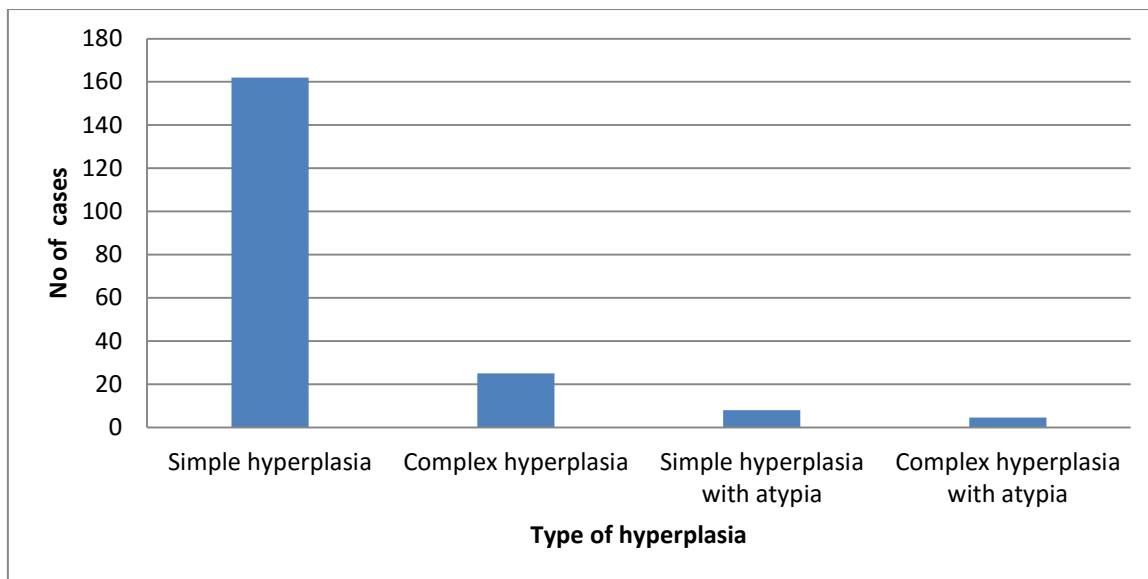
Clinical data of all endometrial hyperplasia cases reveal an important association with anovulatory cycles and hormonal therapy. [Figure 2]



**Fig-1: Age wise distribution of endometrial biopsies**



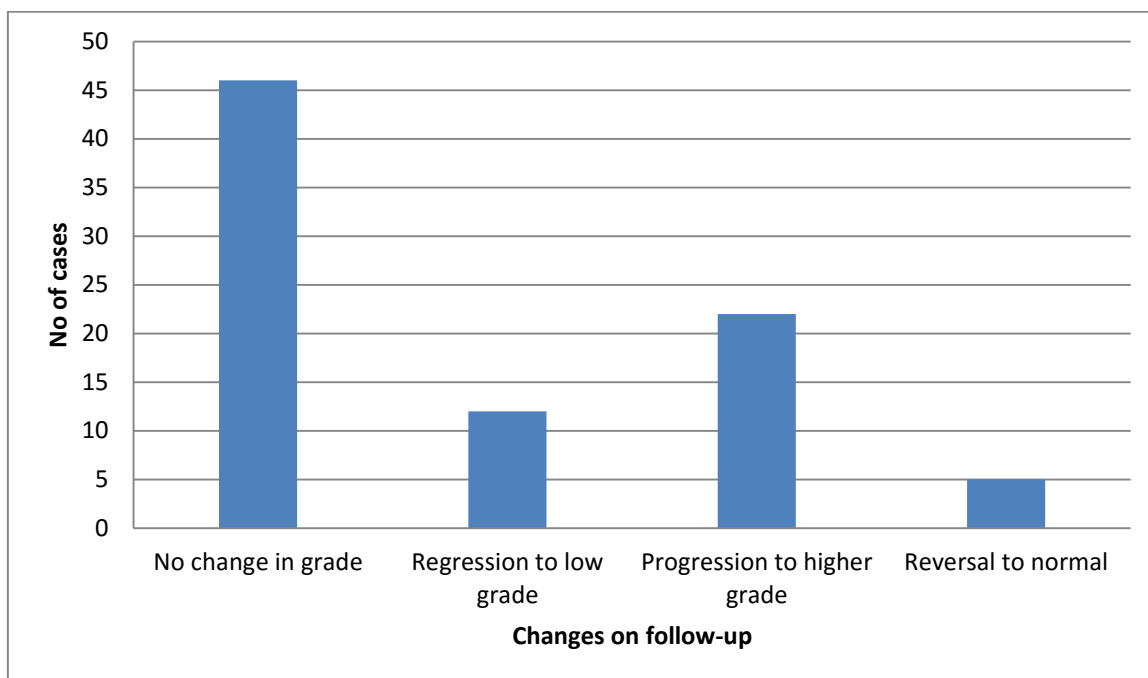
**Fig-2: Association of endometrial hyperplasia cases with clinical conditions**



**Fig-3: Distribution of endometrial hyperplasia cases**

Out of 201 cases of endometrial hyperplasia, only 85 cases were followed up with repeat biopsy due to lack of awareness in rural population. Out of 85 cases, simple hyperplasia 41 cases, complex hyperplasia 29 cases, simple hyperplasia with atypia 8 cases and

complex hyperplasia with atypia 07 cases were reported. In most of these case no change in grade of the lesion was found, progression to higher grade was mainly seen in the cases of complex hyperplasia [Figure 4].



**Fig-4: Distribution of follow-up cases as per changes in repeat biopsy**

**DISCUSSION**

Endometrial hyperplasia is defined as a proliferation of glands of irregular size and shape with an associated increase in the gland/stroma ratio compared with proliferative endometrium [2].

Anovulation occurs at menarche and in perimenopausal women; hence hyperplasia is not usually encountered in young women. We encountered a case of 15 year old female presenting with hyperplasia which is similar to the younger age encountered in other studies [3, 4]. Persistent anovulation or exogenous estrogen exposure being the most important causes of

hyperplasia justifies the more prevalence of hyperplasia in 3<sup>rd</sup> and 4<sup>th</sup> decade as observed in our study similar to the findings of other studies [4, 5, 6].

Besides anovulation, obesity and diabetes seem to have important association with endometrial hyperplasia in our study. Obese diabetics have high insulin resistance and as a result have high plasma insulin levels, which may increase free estrogen levels by decreasing the concentration of sex hormone-binding globulin [7]. Thus, explains the cause of this association.

In our study, simple hyperplasia was the most common pattern but the incidence of complex hyperplasia was comparatively more than other studies [4, 6]. This could be explained by the fact that females in rural settings come late for treatment as well as unscrupulous use of hormonal therapies by local practitioners.

Most of the studies performed in the past suggest that there are more chances of progression to carcinoma in cases of hyperplasia with atypia (22%, 40%) as compared to hyperplasia without atypia (2%, 10%) [1, 8]. In our study, 85 cases were followed up for approximately a period of 1 year. 2 cases of complex hyperplasia with atypia showed conversion to endometrial carcinoma after a period of 7 and 9 months respectively. Most of the cases of simple and complex hyperplasia without atypia showed persistence of lesion without any changes in the grading. These findings closely correlate with the findings of Rao *et al.*; [4].

## CONCLUSION

Take home message:

1. All cases of abnormal uterine bleeding must be addressed as early as possible with proper endometrial sampling.
2. Long term cases of untreated hyperplasia can lead to persistence of disorder or even progression to higher grade and endometrial carcinoma.
3. Anovulatory cycles being the most important association with endometrial hyperplasia point towards further comprehensive studies on hormonal levels with endometrial biopsy follow-up.
4. Complex hyperplasia being slightly higher in percentage in our study as compared to other studies may be an indication for more statistical studies involving the urban and rural female patients.

## ACKNOWLEDGEMENT

We are highly grateful to both the gynaecologists Dr. Aradhana Gupta and Dr. Preeti Sahu for coordinating with us in this study. Working in the

rural area of Chhattisgarh and serving the patients is highly appreciating.

## REFERENCES

1. Kurmen RJ, Kaminski PF, Norris HJ. The behavior of endometrial hyperplasia. *Cancer*. 1985; 56(2):403-12.
2. Scully RE, Bonfiglio TA, Kurman RJ, Silverberg SG, Wilkinson EJ, editors. *Histological typing of female genital tract tumours*. Springer Science & Business Media; 2012 Dec 6; 1-189.
3. Lee KR, Scully RE. Complex endometrial hyperplasia and carcinoma in adolescents and young women 15 to 20 years of age. A report of 10 cases. *International Journal of Gynecological Pathology*. 1989 Sep 1; 8(3):201-13.
4. Rao S, Sundaram S, Narasimhan R. Biological behavior of preneoplastic conditions of the endometrium: A retrospective 16-year study in south India. *Indian Journal of Medical and Paediatric Oncology*. 2009 Oct 1; 30(4):131.
5. Gusberg SB, Kaplan AL. Precursors of corpus cancer: IV. Adenomatous hyperplasia as stage 0 carcinoma of the endometrium. *American journal of obstetrics and gynecology*. 1963 Nov 1; 87(5):662-78.
6. Salma M, Kouser T, Nasar MA. Endometrial Hyperplasia: 5-Years Retrospective Study. *Indian Journal of Pathology and Oncology*. 2016 Apr; 3(2):221-5.
7. Weiderpass E, Persson I, Adami HO, Magnusson C, Lindgren A, Baron JA. Body size in different periods of life, diabetes mellitus, hypertension, and risk of postmenopausal endometrial cancer (Sweden). *Cancer Causes & Control*. 2000 Feb 1; 11(2):185-92.
8. Lacey JV, Ioffe OB, Ronnett BM, Rush BB, Richesson DA, Chatterjee N, Langholz B, Glass AG, Sherman ME. Endometrial carcinoma risk among women diagnosed with endometrial hyperplasia: the 34-year experience in a large health plan. *British journal of cancer*. 2008 Jan 15; 98(1):45-53.