

Original Research Article

A retrospective study to assess the functional outcome of tibial plateau fractures treated surgically with locking plate by Mippo technique-series of 36 cases

Dr Vinay Kumar Gunjali¹, Dr H P Rajagopal², Dr Ramesh LJ³

¹Senior Resident, Department of Orthopaedics, St. John's Medical College Hospital, Bangalore, Karnataka, India

²Associate professor, ³Professor

St. John's Medical College Hospital, Bangalore, Rajiv Gandhi University of Health Sciences (RGUHS), Bangalore, Karnataka, India

***Corresponding author**

Dr Vinay Kumar Gunjali

Email: vinayortho9@gmail.com

Abstract: Tibial plateau fractures are usually followed by high-energy trauma. These fractures are difficult to treat because of the involvement of the articular surface, the comminution, and condition of the soft tissues. This retrospective study was conducted between May 2013 to July 2015, 36 patients with closed displaced tibial plateau fractures underwent internal fixation using locking plates by MIPPO technique at St. John's medical college hospital, Bangalore. There were 27 males and 9 females with an average age of 39 years (range 25-56 yrs). Right knee was involved in 23 cases and Left knee in 13 cases. Mode of injury was road traffic accidents and fall from height. Mean age of the patients was 39 years (range 25-56 years). 17 excellent, 12 good, 5 fair and 2 poor results were observed in the study. All fractures healed after a mean period of 13 weeks (range 8-22 weeks) without bone grafting. A complication encountered was knee Stiffness in 2 patients. No complications were associated with the plate in this study. The use of minimally invasive technique provides good to excellent functional outcome with various advantages.

Keywords: Tibial plateau fractures, MIPPO, Locking plate, Rasmussen's score

INTRODUCTION:

Tibial plateau fractures are usually followed by high-energy trauma. These fractures are difficult to treat because of the involvement of the articular surface, the comminution, and condition of the soft tissues. Internal fixation with locking plates following the principles of MIPPO (Minimally Invasive Percutaneous Plate Osteosynthesis) provides effective and satisfactory fracture reduction with good results in terms of functional outcome. The aim of the study is to restore the congruity of articular surface of tibial plateau, to fix the fracture with a rigid and stable implant using MIPPO technique and to allow early rehabilitation.

MATERIALS & METHODS:

This retrospective study was conducted between May 2013 to July 2015, 36 patients with closed displaced tibial plateau fractures underwent internal fixation using locking plates by MIPPO technique at St. John's medical college hospital, Bangalore. There were

27 males and 9 females with an average age of 39 years (range 25-56 yrs). Right knee was involved in 23 cases and Left knee in 13 cases. Mode of injury was road traffic accidents and fall from height.

Inclusion criteria:

- Age group : >18years
- Displaced Tibial plateau fractures (Schatzker's)
- Fractures operated within one week of injury

Exclusion criteria:

- Fractures associated with neurovascular injury
- Ipsilateral fractures other than tibial plateau
- Compound fractures
- Associated head injuries

SCHATZKER'S Classification for Tibial Plateau Fractures [1]:

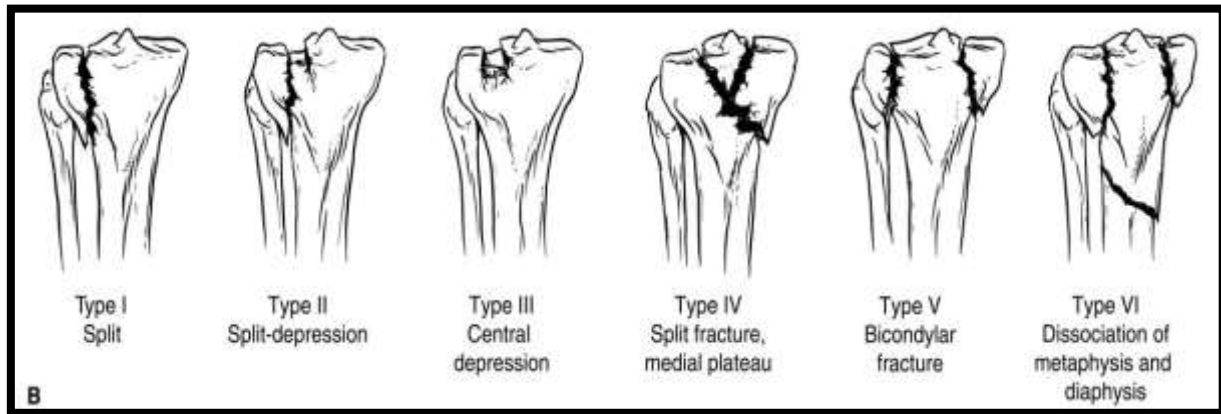


Fig-1: Schatzker J. Fractures of the tibial plateau

PROCEDURE:

Pre-operative planning:

- AP and Lateral radiographs were used to know the amount of displacement, depression and angulation. CT scan with 3-dimensional reconstruction was performed in all cases to classify the fractures.
- Operative treatment was performed under general or spinal anaesthesia. Patients were placed supine on a radiolucent table with or without traction. Depressed fragments were elevated & condylar fragments were reduced

percutaneously by reduction forceps under fluoroscopic guidance. An incision of 5 to 6 cm over medial, lateral or both sides was made according to the fracture type. A Locking plate of an appropriate length was chosen. A submuscular and/or subcutaneous plane was created & the plate was slid. The plate was fixed with screws percutaneously under C-Arm. In some patients with bicondylar fractures, cannulated cancellous screws were used along with plate.

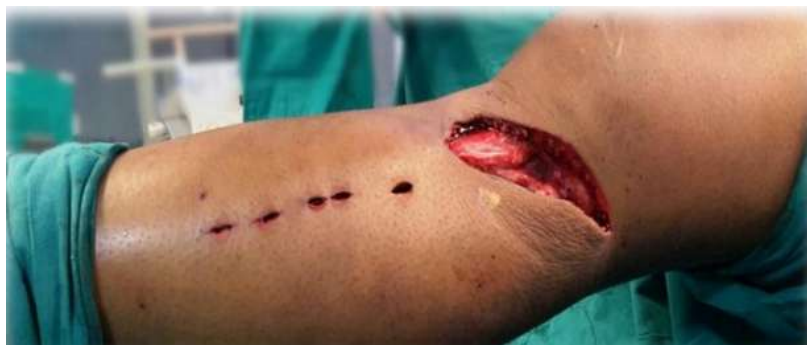

Fig-2: Position and Approach

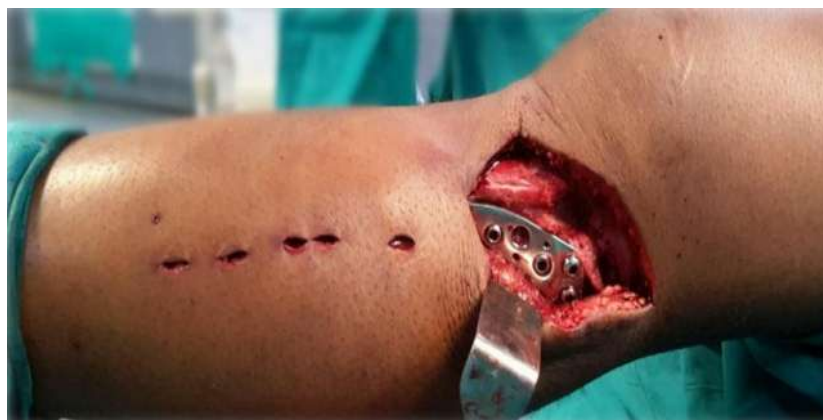

Fig-3: Locking plate in situ – MIPPO Technique

Post op management:

- The knee was immobilized in extension knee brace. Isometric quadriceps exercises were started from first post operative day. Knee mobilization was started on third post operative day to two weeks depending on the stability of fracture fixation. Patients were mobilised with non weight bearing walker walking at 8-10weeks. Subsequently, partial

weight bearing and full weight bearing was allowed according to the fracture union.

- Follow up of patients was assessed at 6 weeks, 3 months, 6 months and one year respectively.
- Functional outcome of the knee was assessed using the Rasmussen's knee scoring system at 6 months and 1 year.

Table-1: Rasmussen's functional knee score

Rating	Pain	Clinical features			Stability
		Walking capacity	ROM	Clinical signs	
Excellent	No	Normal	Normal	No	Normal
Good	Minimal	Walking outdoor for at least 1 h	75% of normal	+	Minimal
Fair	Occasional ache	Walking outdoor for 15 min	>50% of normal	Swelling, ++	Instability in flexion
Poor	Pain at rest	Walking indoor only	50% of normal or less	+++	Instability in flexion as well as in extension

ROM: Range of motion

RESULTS:

- Mean age of the patients was 39 years (range 25-56 years). 17 excellent, 12 good, 5 fair and 2 poor result were observed in the study. All fractures healed after a mean time of 13 weeks

(range 8-22 weeks) without bone grafting. Complications encountered were knee Stiffness in 2 patients. No complications were associated with the plate in this study.

Table-2: Distribution of Gender

Gender	Distribution (n=36)	
	Number	Percentage
Male	27	75.00
Female	9	25.00
Total	36	100.00

Table-3: Side of Injury

Side	Distribution (n=36)	
	Number	Percentage
Right	23	64.00
Left	13	36.00
Total	36	100.00

Table-4: Mode of Injury

Nature of trauma	Distribution (n=36)	
	Number	Percentage
Road traffic accident	25	69.00
Fall	11	31.00
Total	36	100.00

Table-5: Type of Fracture:

Schatzker's Classification	Distribution (n=36)	
	Number	Percentage
Type 1	8	22.00
Type 2	4	11.00
Type 3	0	00.00
Type 4	6	17.00
Type 5	10	28.00
Type 6	8	22.00
Total	36	100.00

Table-6: Final Outcome:

Outcome	Distribution (n=36)	
	Number	Percentage
Excellent	17	47.00
Good	12	33.00
Fair	5	14.00
Poor	2	06.00
Total	36	100.00

Case 1
Clinical Photographs

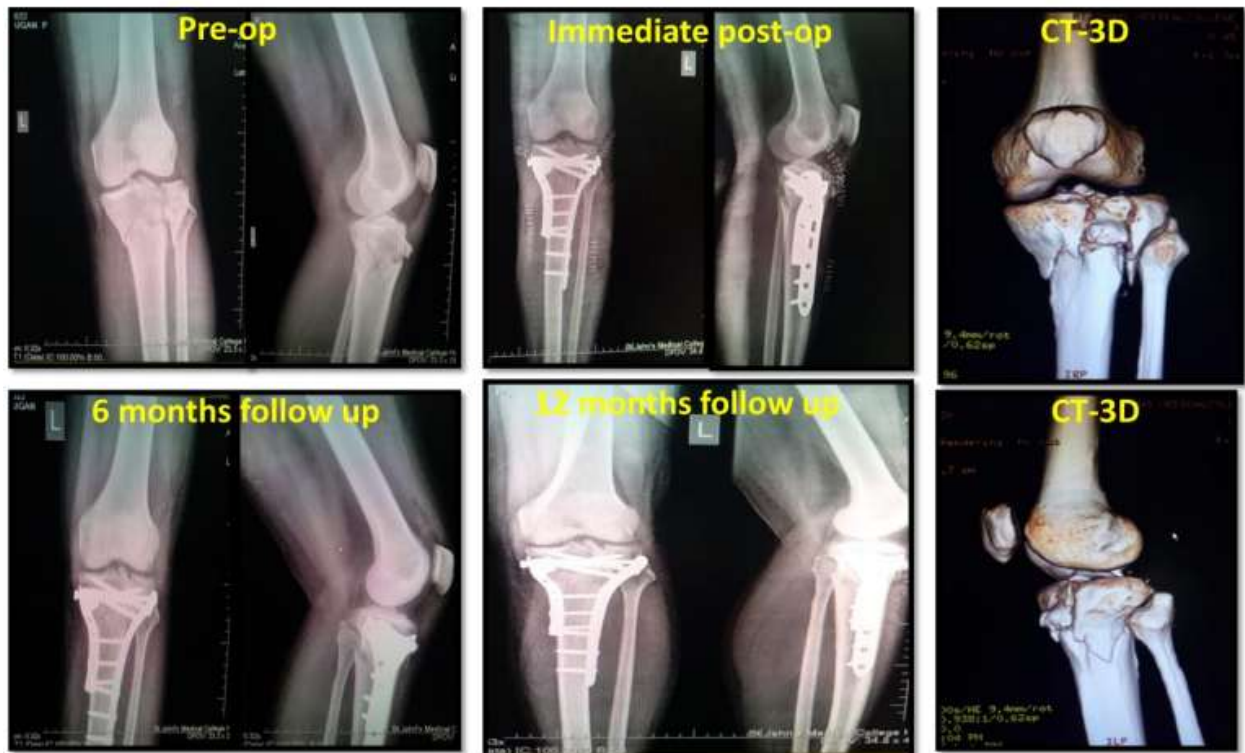


Fig-2: Case 1- Type 5 Tibial Plateau fracture:

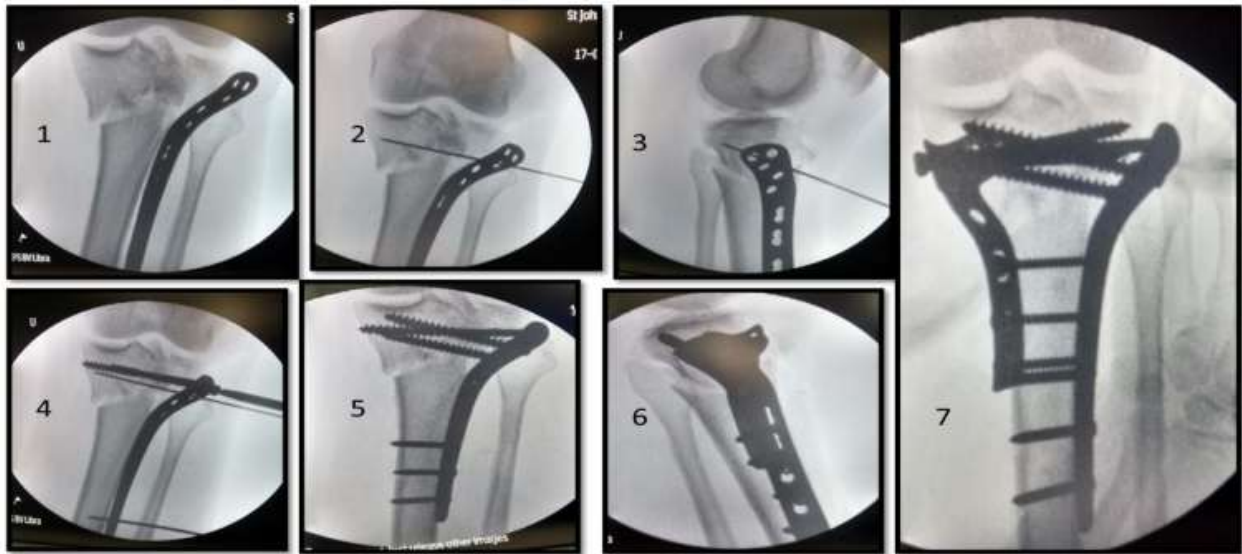


Fig-3: C-arm intra operative images:

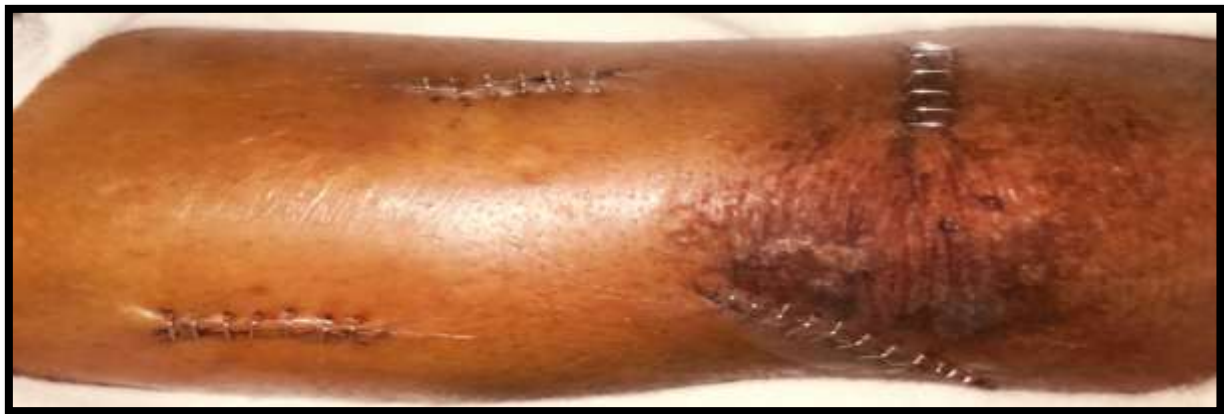

Fig-4: Immediate post operative picture showing minimal incision:

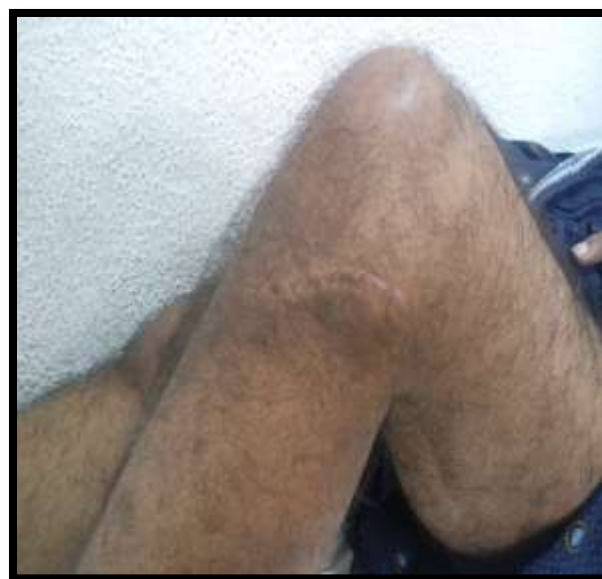

Fig-5: Follow up picture showing healed minimal scar:

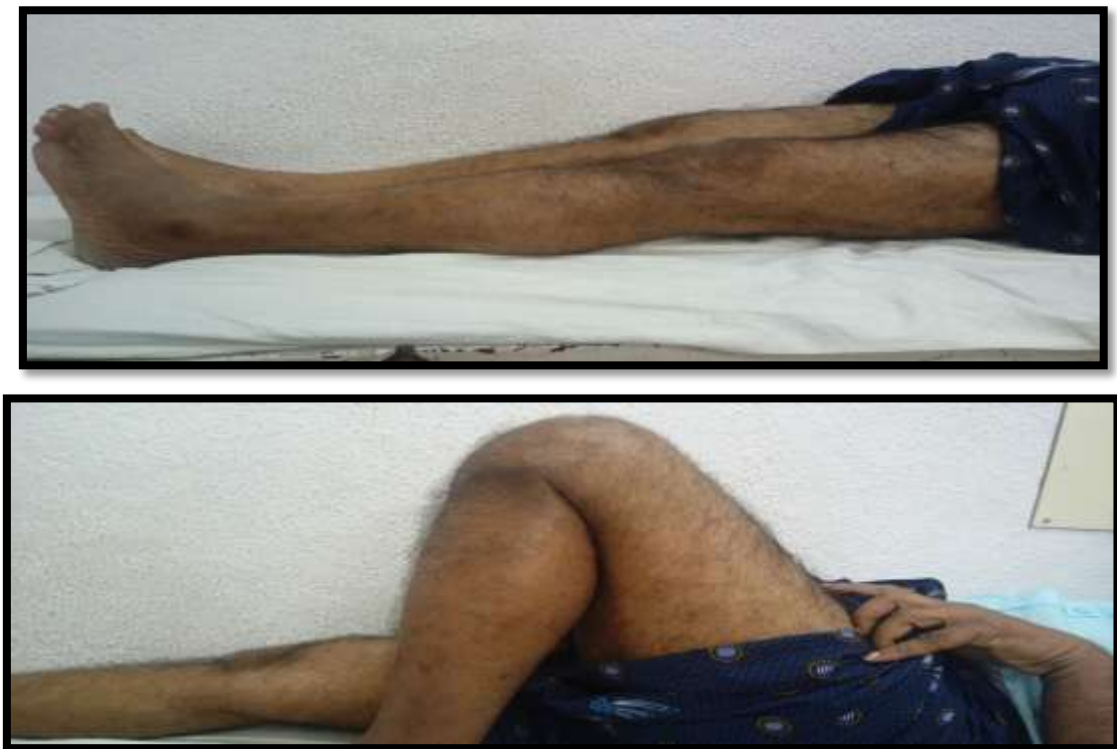

Fig-6: Excellent functional outcome:

Case 2

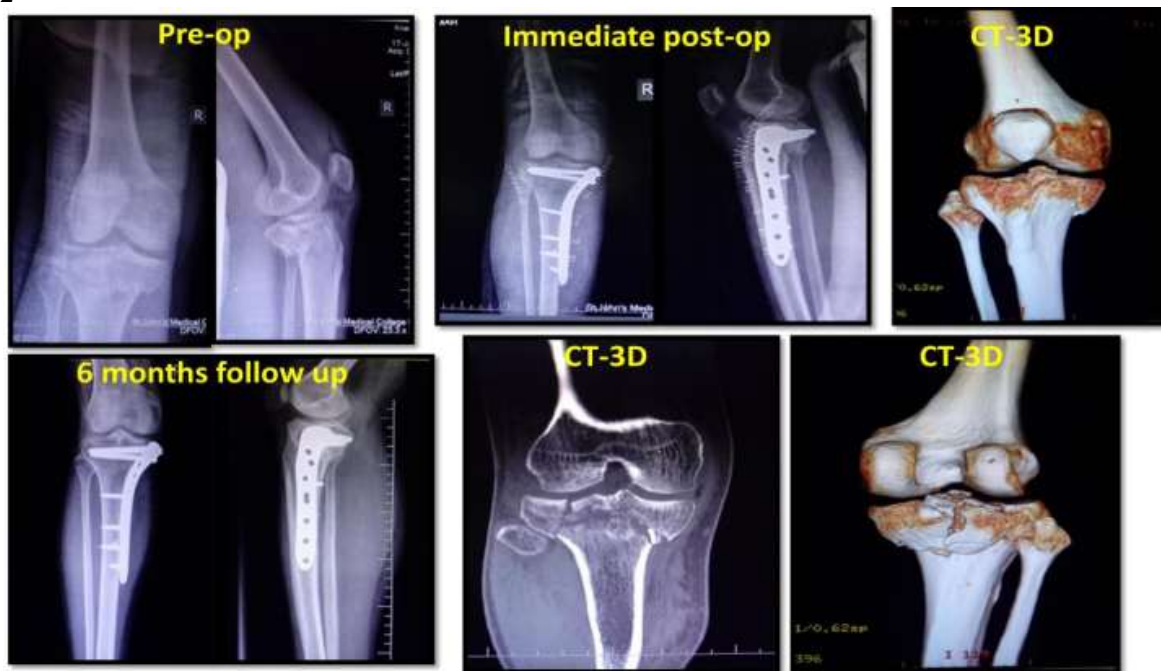


Fig-7: Type 5 Tibial plateau fracture:

Case 3

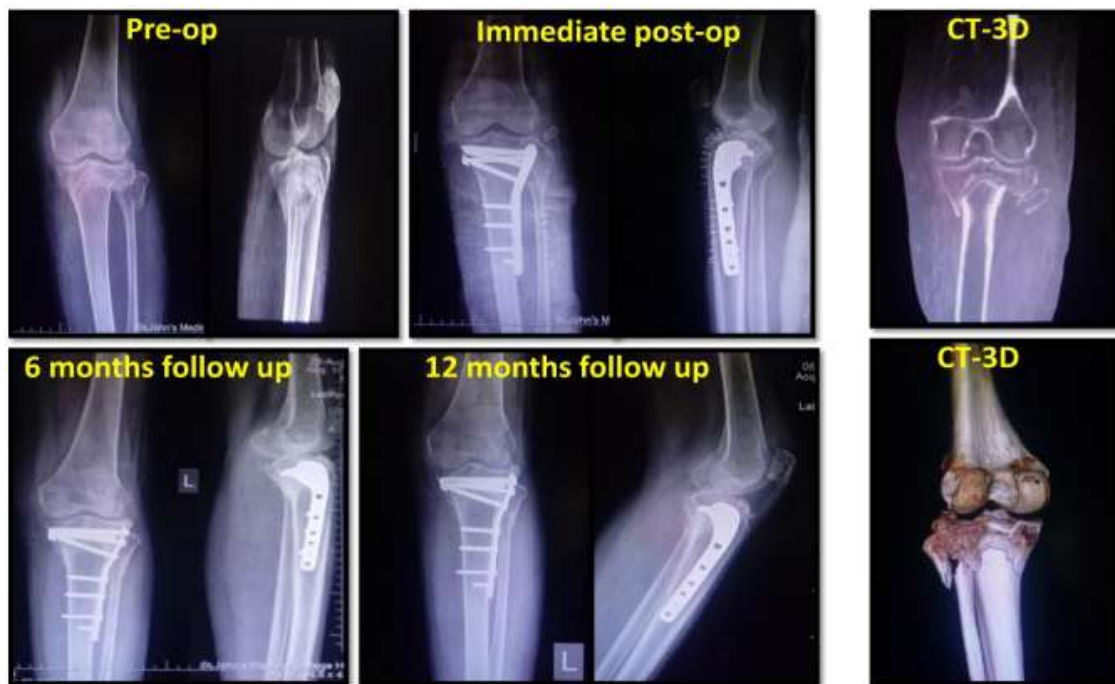

Fig-8: Type 5 Tibial plateau fractures

Case 4

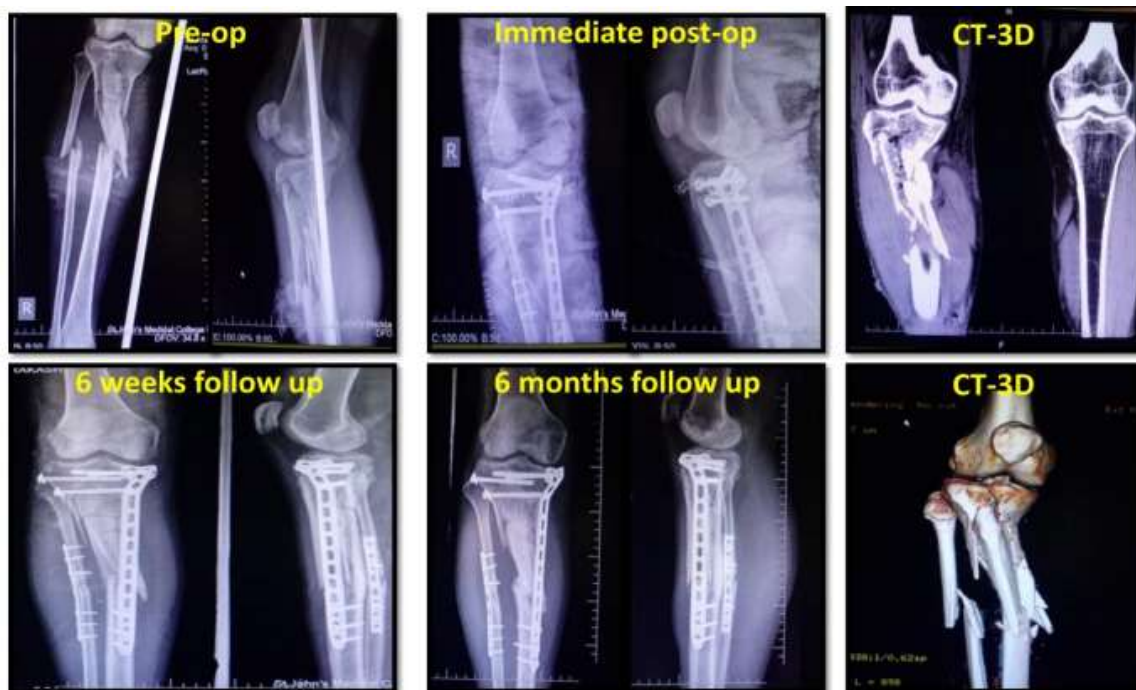

Fig-9: Type 6 Tibial plateau fracture

DISCUSSION:

- Tibial plateau fractures occur in an important load-bearing joint therefore anatomical restoration of articular surface and rigid internal fixation is mandatory to minimize pain, stiffness, deformity and instability. As

we know ORIF necessitates extensive soft tissue stripping for adequate exposure, hence is associated with a high incidence of complications like non union, wound dehiscence, infection and stiffness. An important factor in the outcome of tibial

plateau fractures is the preservation of adequate anatomical reduction [3].

- MIPPO enables indirect fracture reduction & percutaneous implant placement with added advantages of minimal incision, minimal soft tissue handling, minimal damage to periosteum & minimal bleeding [4]. Favourable outcome is not due to MIPPO but less extensive dissection of soft-tissue envelope and devitalisation of fracture fragments. In a study of ORIF, 20% of patients developed superficial or deep infections despite acceptable functional outcome [5]. In our study, all patients had fracture healing with no wound dehiscence or infection.
- MIPPO results in lower incidence of soft-tissue complications and achieves better outcome than ORIF does. Intraarticular fractures are commonly associated with late-onset post-traumatic secondary arthritis if they are inadequately treated. Long-term follow-up is therefore necessary. One limitation of this study was a mean follow-up period of 9 months.

fractures. Journal of Orthopaedic Surgery 2012; 20(1):42-7.

CONCLUSION:

- The cornerstone in the treatment of tibial plateau fractures is anatomical reduction and rigid internal fixation followed by early knee mobilisation and partial weight bearing during bone healing.
- The use of minimally invasive technique provides good to excellent functional outcome with various advantages.
- Standard fracture classification, fixation of fracture by MIPPO technique and evaluating the knee function using scoring system has helped us to understand and address these fractures effectively.

REFERENCES:

1. Schatzker J; Fractures of the tibial plateau. In: Operative Orthopaedics, ed by MW. Chapman. Philadelphia: J.B. Lippincott; 1998; 421-34.
2. Rasmussen PS; Tibial condylar fractures: impairment of joint stability as an indication for surgical treatment. J Bone Joint Surg Am 1973; 55: 1331-50.
3. Jackson AL, Stamatios AP, Charles M, Charalampos GZ; Tibial plateau fractures treated with the less invasive stabilization system. Int Orthop (SICOT) 2007; 31: 415-8.
4. Ruslan GS, Razak M; The results of surgical treatment of tibial plateau fractures. Med J Malaysia. 1998; 53(Suppl.) A: 35-41.
5. Hasnain Raza, Pervaiz Hashmi; Minimally invasive plate osteosynthesis for tibial plateau