

Research Article

Diagnostic efficacy of Color Doppler combined with Gray scale ultrasonography over Modified Alvarado score for diagnosing appendicitis

Swarnava Tarafdar¹, Ankur Malhotra², A.T. Tayade³

¹Department of Radiodiagnosis, Mahatma Gandhi Institute of Medical Sciences, Sevagram-442102, Wardha, Maharashtra, India

²Department of Radiodiagnosis, Mahatma Gandhi Institute of Medical Sciences, Sevagram-442102, Wardha, Maharashtra, India

³Head of the Department, Department of Radiodiagnosis, Mahatma Gandhi Institute of Medical Sciences, Sevagram-442102, Wardha, Maharashtra, India

***Corresponding author**

Swarnava Tarafdar

Email: dr.tarafdarswarnava@gmail.com

Abstract: This is a prospective study conducted on 289 patients of 11 to 30 years age group with clinically suspected appendicitis. After Modified Alvarado scoring, ultrasonography (USG) was done. Each patient was then subjected to surgery and the removed appendix was sent for histopathological examination. The histopathological diagnosis was considered as Gold Standard. In comparison to clinical assessment (Modified Alvarado score), Gray scale USG was found better in detecting appendicitis (USG had sensitivity 89.5%, specificity 81%, positive predictive value 89.4 %, negative predictive value 80%, where as modified Alvarado score showed sensitivity 74 %, specificity 80.8 %, positive predictive value 88%, negative predictive value 61.5 %). The Gray scale and Color Doppler when used in combination showed the highest efficacy in comparison to Gray scale when used alone (Combined Gray scale and Color Doppler USG sensitivity 89.4 %, specificity 94.9 %, positive predictive value - 97 %, negative Predictive value 82.4 %). Therefore, Ultrasonography is definitely better than modified Alvarado score in diagnosing appendicitis and using Color Doppler in addition to Gray scale further improves diagnostic efficacy.

Keywords: Acute appendicitis, Appendicectomy, Alvarado score, Color Doppler, Gray scale, Suppurative appendicitis.

INTRODUCTION

Acute appendicitis is the most common abdominal surgical emergency in all individuals especially in the age group 11 to 30 years [1]. Sometimes, patients present with atypical clinical features and non-specific physical findings and evaluation of these patients becomes very challenging if done only on clinical grounds [2]. Delay in diagnosis of such cases can lead to complications such as perforation and peritonitis [2-4]. A clinician decision to operate can lead to removal of a normal appendix in 15–30% of cases [5-7]. So, immediate surgery in patients without appendicitis definitely adds up to surgical costs, complications and unnecessary use of valuable hospital resources. Thus truly said “Even the most experienced surgeons may remove normal appendix or sit on those that have perforated” [8].

Therefore, for diagnosing appendicitis a reliable modality is required which should be accurate i.e. with a highest sensitivity and specificity and is capable of assessing the extent of the disease [9]. The

modality should be cost effective i.e., the cost of the examination should be less than the consequences of treating the patient without the benefit of the information derived from the examination [9, 10]. The examination should be rapid, both in the length of the study and in the availability of the diagnostic information. Also the modality should be noninvasive [9]. Ultrasound fulfils all these requirements satisfactorily. Graded compression USG technique is still the first line method in diagnosing appendicitis [11-13]. Previous studies had shown that the Color Doppler USG is a powerful imaging tool that definitely improves the diagnostic accuracy in patients with clinically equivocal appendicitis [11, 14-19]. It also helps in diagnosing early changes of appendicitis [20].

MATERIAL AND METHODS

This prospective study was carried out in the Department of Radiodiagnosis, M.G.I.M.S., Sevagram, Maharashtra. This study includes sonographic evaluation of 289 patients with clinically suspected appendicitis in 11-30 years age group of both sexes

from 2011 to 2014. Diagnosed or follow up cases of right lower abdominal pain and the patients who were managed only conservatively were excluded from the study. Approval for the study was obtained by institutional ethical committee. The study was done in PHILIPS HD11 XE 3D/4D Color Doppler USG machine using both Linear Transducer (frequency range 3-12 MHz) and curvilinear Transducer (frequency range 2-5 MHz). A written informed consent was obtained of each patient. The relevant clinical history was taken, clinical examination was done of each patient and

modified Alvarado scoring was done on basis of clinical examination findings and laboratory investigation results before procedure. The Modified Alvarado scoring is illustrated in Table 1. The score of 7 or more was considered positive for appendicitis [5]. To decrease intra-observer variability the average value of three measurements was taken. The clinical history, examination and USG findings along with intraoperative findings and histopathological results of each patient were entered in a predesigned Performa.

Table 1: Modified Alvarado score [21]

Symptoms	Score
Migratory right iliac fossa pain	1
Anorexia	1
Nausea and vomiting	1
Signs	
Tenderness (right iliac fossa)	2
Rebound tenderness	1
Elevated Temperature	1
Lab Investigations	
Leucocytosis	2
Shift to left	1
Total Score	10 (7 or more score is strongly predictive of acute appendicitis)

Technique of examination [22]:

Examination was initially done in full bladder. After about 10 min search for appendix, other causes of pain in right iliac fossa were ruled out. Then patient was asked to empty the bladder and again the search was continued. Scanning was also done in supine and lateral decubitus position (if retrocaecal appendix is suspected). Scanning was done in both longitudinal and transverse planes. Transducer was placed transversely below the edge of right hepatic lobe, in front of right kidney and moved slowly down to right iliac fossa along the line of ascending colon [23]. Cecum was identified initially and then the appendix was traced, which is draped over right iliac fossa anterior to iliopsoas muscle. Examination was done in both linear and curvilinear probes. Graded compression USG [12] technique was utilized in the examination with exerting gentle compression with high frequency transducer using both hands in same way when palpating abdomen. Normal and gas filled loops of intestine are either displaced from the field of vision or compressed between anterior and posterior abdominal walls.

While studying vascularity in appendix, Color gain is increased until clutter is seen and then it is reduced just enough to remove the clutter from the appendiceal wall. Doppler examination findings can be summarized as: presence or absence of Color Doppler signals and whether color flow is increased or normal. A suppurative appendicitis showed greater circumferential flow in its wall than a normal appendix. A gangrenous appendicitis is diagnosed when Color Doppler signals disappears with loss of echogenicity in its wall on Gray Scale. An inflamed surrounding mesentery and omentum shows increased flow on Doppler. The Gray Scale and Color Doppler USG findings of appendicitis are shown in Figure 1 to 11.

Statistical analysis was done by using chi square test and predictive values of diagnostic tests. The software used in the analysis was SPSS 17.0 and Graph Pad Prism 5.0 and $p < 0.05$ is considered as level of significance. The sensitivity, specificity, positive predictive value, negative predictive value of the Alvarado score, Gray scale USG and Gray scale and Color Doppler USG in combination was calculated by 2 x 2 tables.

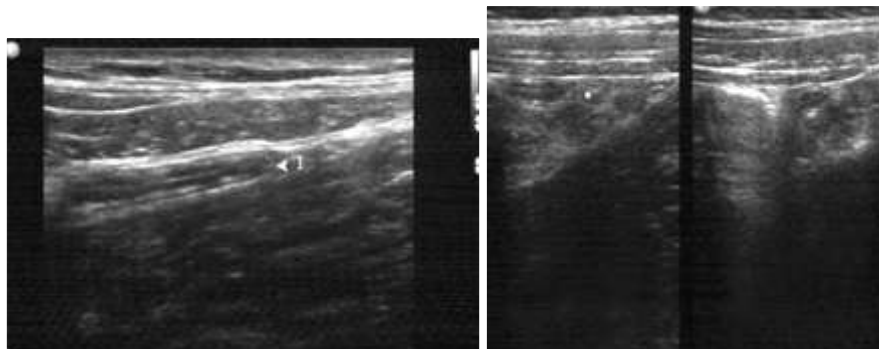


Fig-1:

Fig-2:

Fig. 1 & 2: Normal appendix - blind-ended, tubular, compressible intestinal loop which is continuous with the cecum and has a diameter of less than 6 mm.

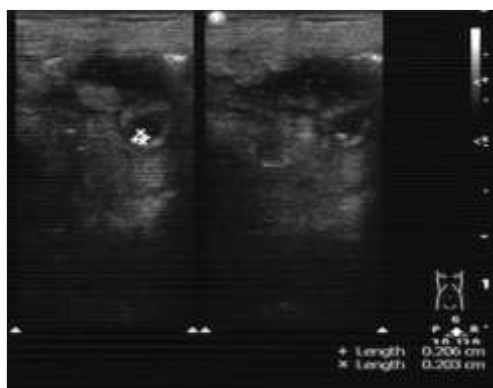


Fig 3: Appendicoliths - bright echogenic focus with distal acoustic shadowing, its visualization is another contributory finding in diagnosing appendicitis.

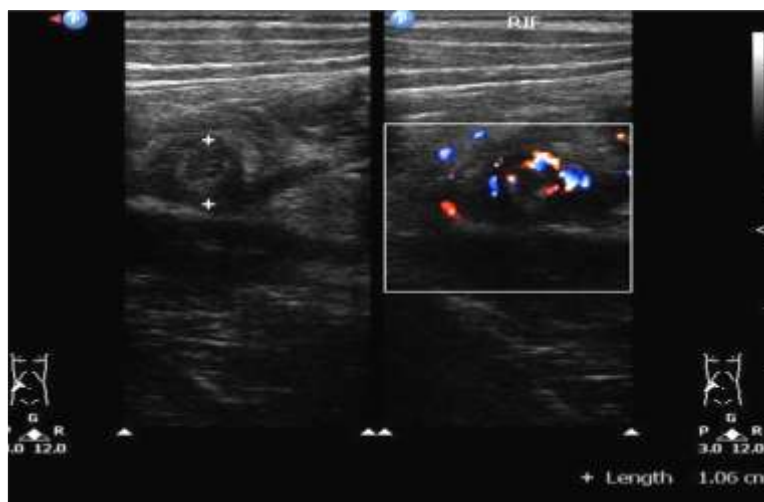


Fig 4: Suppurative appendicitis - aperistaltic, noncompressible, blind-ended, tubular structure with laminated continuous wall arising from base of cecum. Appendicitis is characterised by a wall thickness > 2 mm & diameter > 6 mm. On Color Doppler study there is increased vascularity in appendiceal wall.

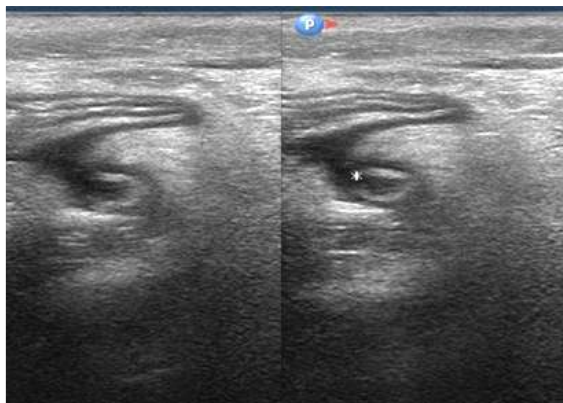


Fig 5: Perforated appendicitis - discontinuity in wall layers, asymmetry of wall thickness, presence of air or fluid collection with echoes around appendix.

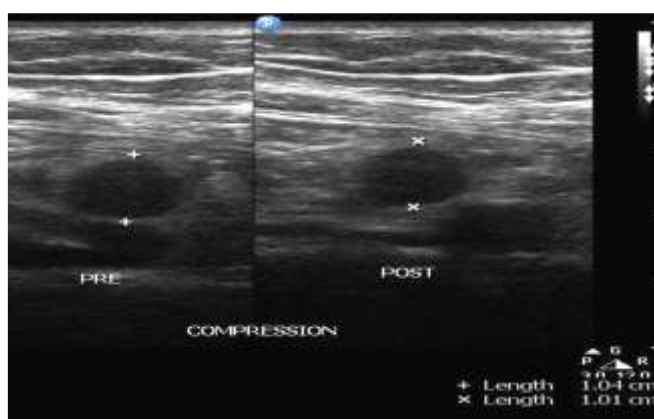


Fig 6: Gangrenous appendicitis focal loss of echogenic submucosal layer of the appendiceal wall with surrounding echogenic fat.

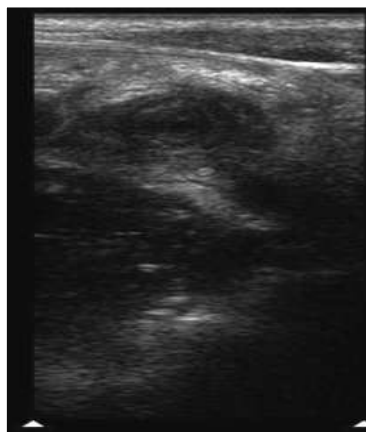


Fig 7: Appendicular lump - large mass of non compressible echogenic fat was seen around appendix forming a mass.

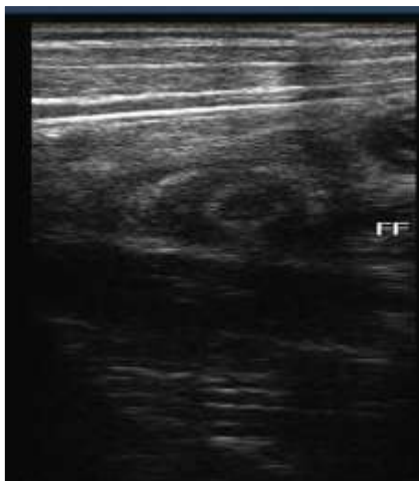


Fig 8: Peri appendiceal collection

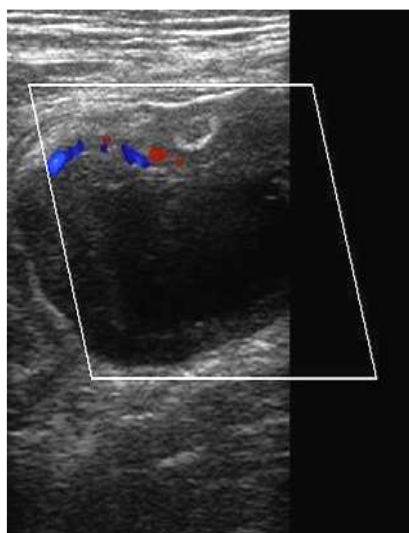


Fig. 9 : Appendicular abscess - localized fluid collection was seen which is walled off by adjacent greater omentum and small-bowel loops. When a complex, hypo echoic mass adjacent to cecum or appendix was present, even though the inflamed appendix is not visualized, appendicular abscess will be suggestive. Color Doppler study shows increased peripheral vascularity.

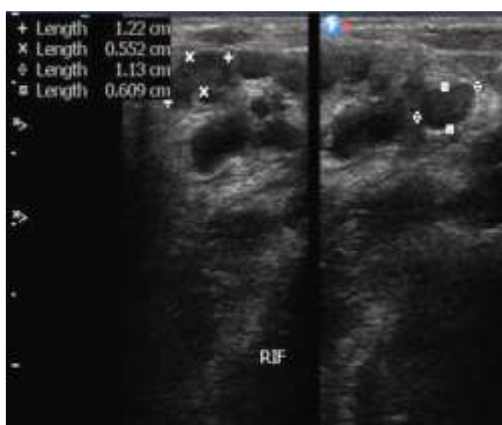


Fig. 10: Mesenteric Lymphadenopathy

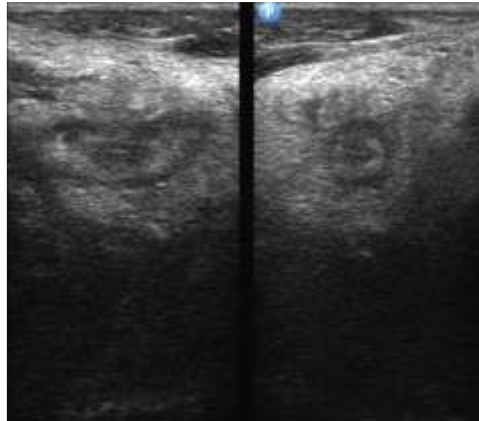


Fig. 11: Surrounding echogenic mesentery

RESULTS

This study includes 289 clinically suspected cases of appendicitis who were exposed to USG and in whom appendicectomy was done. The removed appendix was sent for histopathological evaluation. The histopathological study was considered as final. So, the operated cases were divided into 2 groups on basis of histopathological finding i.e. whether positive or negative for appendicitis.

Out of 289 cases, in 175 cases which were diagnosed positive for appendicitis by USG (both Gray Scale and Color Doppler), histopathology showed appendicitis in 170 cases and ruled out appendicitis in rest 5 cases. Out of 114 cases where USG was normal, histopathology showed appendicitis in 20 cases and ruled out appendicitis in rest 94 cases. Therefore, out of

total 289 cases, histopathology declared 190 cases as positive (Group I) for appendicitis and 99 cases (Group II) as negative for appendicitis. The distribution of 289 operated cases on basis of ultrasound and histopathological diagnosis for appendicitis is demonstrated in Table 2. The sex distribution in 190 histopathologically proved appendicitis is demonstrated in Fig.12. The distribution of 289 operated cases according to their presenting symptoms and signs are demonstrated in Figure 13 &14 respectively. Distribution of 289 cases according to the laboratory investigation (leukocytosis) is depicted in Figure 15. Table 3 shows distribution of cases according to USG findings. The efficacy of Alvarado score, Gray scale ultrasonography and Gray scale Combined with Color Doppler USG is depicted in Table 4. The p value of the study is significant (< 0.05).

Table 2: Distribution of 289 operated cases on basis of USG and histopathological diagnosis for appendicitis.

USG DIAGNOSIS (Color Doppler + Gray scale) (n=289)	FINAL HISTOPATHOLOGICAL DIAGNOSIS (GOLD STANDARD)	
	Positive	Negative
Positive	170 (True Positive)	5(False Positive)
Negative	20 (False Negative)	94(True Negative)

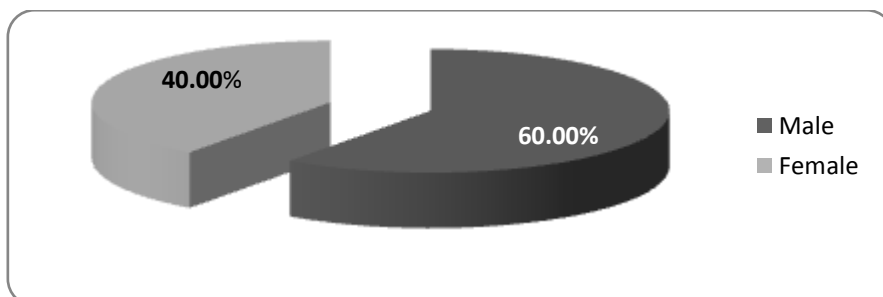


Fig.12: Sex distribution in 190 cases of histopathologically proved appendicitis

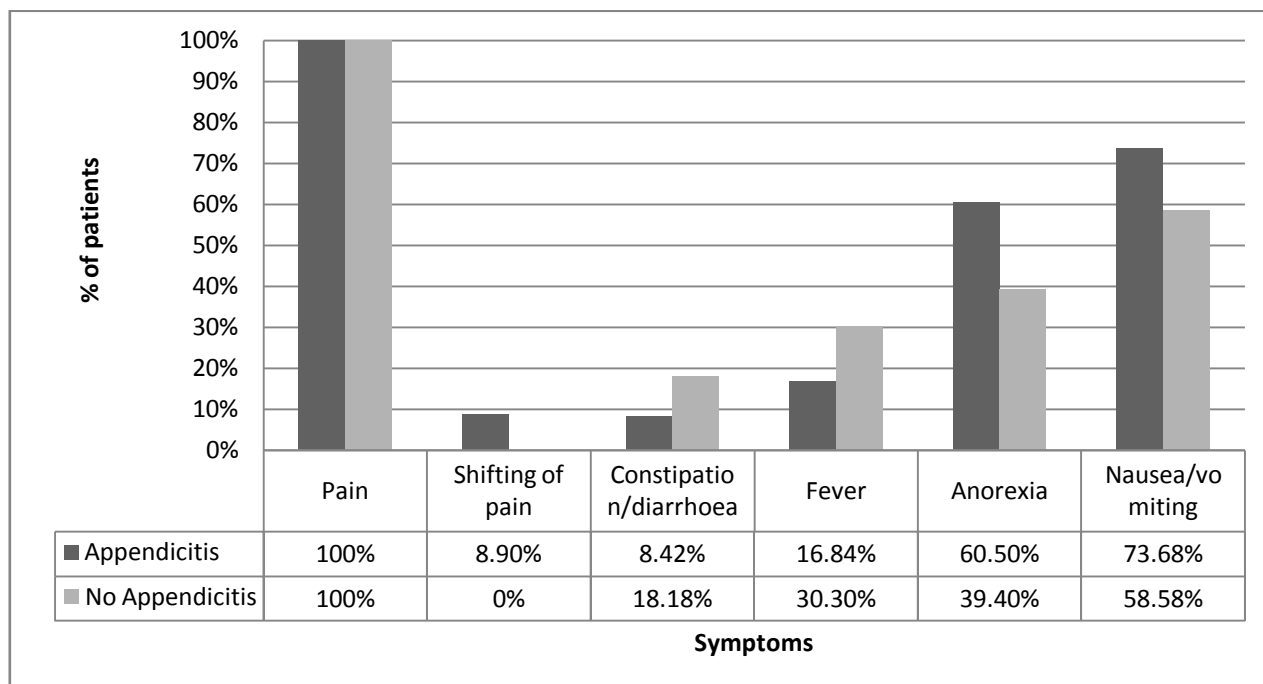


Fig. 13: Distribution of 289 operated cases according to their presenting symptoms

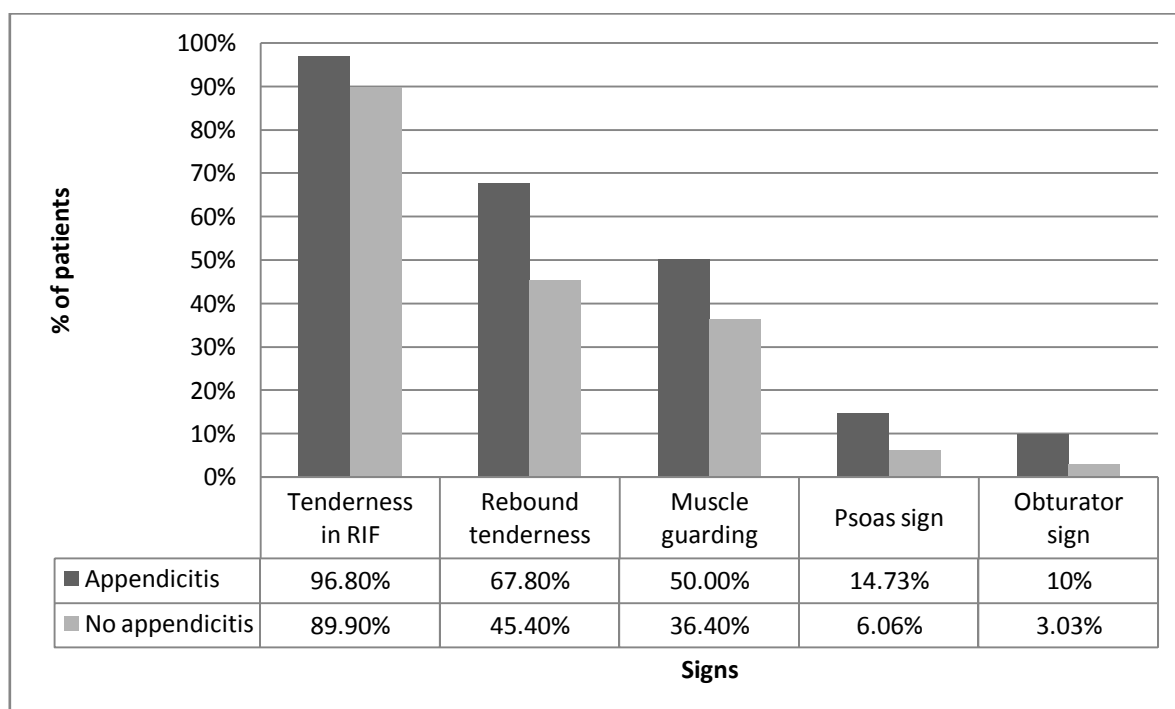


Fig. 14: Distribution of 289 cases according to their presenting signs

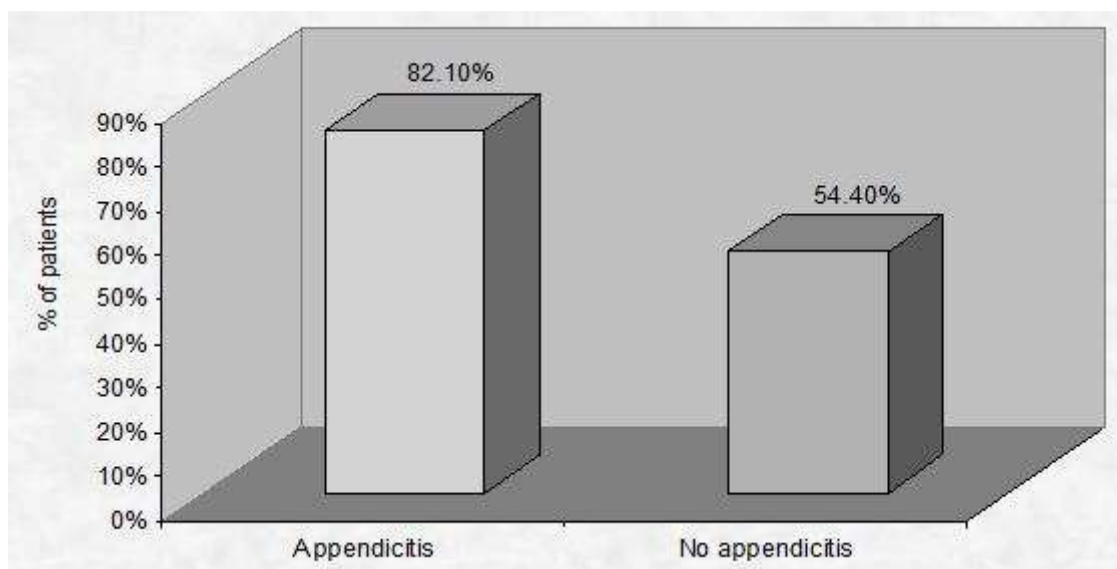


Fig. 15: Distribution of 289 cases according to the laboratory investigation (leukocytosis)

Table 3: Distribution of cases according to their USG findings

USG findings	Appendicitis (190)	%	No appendicitis (99)	%	χ^2 -value	p-value
Probe tenderness	134	70.5%	40	40.4%	16.46	P<0.0001
Wall thickness > 2 mm	110	57.8%	9	10%	51.34	P<0.0001
Appendicoliths	32	16.8%	3	3%	10.89	0.001
Perapendiceal collection	94	49.4%	27	27.3%	10.27	0.001
Maximum outer diameter ≥ 6	100	52.6%	1	1%	68.59	P<0.0001
Discontinuity of wall (Perforated appendix)	11	5.8%	0	0%	6.18	0.012
Gangrenous appendicitis	7	3.68%	0	0%	4.08	0.04
Appendicular abscess	7	3.68%	0	0%	4.08	0.043
Appendicular lump	18	9.4%	0	0%	9.42	0.002
Mesenteric lymphadenopathy	54	28.42%	42	42.4%	4.30	0.03
Surrounding echogenic mesentery	170	89.4%	23	23.2%	78.79	P<0.0001

Table 4: Efficacy of Alvarado score, Gray scale USG and Gray scale Combined with Color Doppler USG.

	Alvarado score	Gray scale ultrasonography	Grade scale combined with Color Doppler ultrasonography
Sensitivity	74%	89.5%	89.4%
Specificity	80.8 %	81%	94.9%
Positive predictive value	88%	89.9%	97%
Negative predictive value	61.5%	80%	82.4%

DISCUSSION

Appendicitis has been always a mysterious aspect throughout times. Ultrasonography is relatively accurate, cost effective, rapid, non-invasive, lacks risk of ionizing radiation and is safe imaging modality for evaluation of appendicitis [14]. It does not require sedation or contrast agents.

In the present study, appendicitis was found more common in males than in females in 11 to 30 years age group patients with male female ratio was 1.5:1. Clinical features such as nausea, vomiting and anorexia are predominantly a feature of appendicitis whereas pain, fever, constipation and diarrhoea are not

specific for diagnosing appendicitis as were more common in patients with no appendicitis in present study. Tenderness in right iliac fossa, rebound tenderness, muscle guarding, Psoas sign and obturator sign are significant clinical signs in diagnosing appendicitis. Similarly leucocytosis is more significant feature in diagnosing appendicitis.

USG findings of periappendiceal echogenic mesentery, probe tenderness in right iliac fossa, thickened appendiceal wall > 2 mm, Maximum outer diameter \geq 6 mm, periappendiceal fluid collection and appendicolith are reliable indicators in diagnosing appendicitis on Gray scale as were significantly common in patients with appendicitis in the present study.

When appendicitis was diagnosed on basis of Alvarado score alone, it detected 140 patients correctly for appendicitis and ruled out appendicitis in 80

patients. However Alvarado score missed 50 cases of appendicitis and 19 cases were falsely diagnosed as positive for appendicitis.

The Gray scale USG alone detected 170 patients correctly for appendicitis and ruled out appendicitis in 80 patients. The gray scale USG missed 20 cases of appendicitis and 19 cases were falsely diagnosed as positive for appendicitis.

When Gray scale and Color doppler USG findings were combined together than 170 patients were diagnosed correctly for appendicitis and also appendicitis was correctly ruled out in 94 patients. 5 cases were diagnosed falsely as positive for appendicitis and in 20 cases appendicitis was missed. The sensitivity, specificity, positive predictive value and negative predictive values of present study are comparable to other standard studies [5, 11, 24, 25, 26]. The findings are illustrated in Table 5.

Table 5: Efficacy of Modified Alvarado Score, Gray Scale and Gray Scale combined with Color Doppler

	Detected appendicitis correctly	Ruled out appendicitis correctly	Missed cases	Falsely diagnosed	Total
Modified Alvarado Score	140	80	50	19	289
Gray Scale	170	80	20	19	289
Gray Scale & Color Doppler	170	94	20	5	289

CONCLUSIONS

Clinical diagnosis based on symptomatology alone is not sufficient to make or confirm the diagnosis of the appendicitis, thus necessitating the need to be subjected for USG for the confirmation of the diagnosis. Gray scale Ultrasound alone is superior to Alvarado scoring in diagnosing appendicitis. Gray scale and Color Doppler ultrasound when used in combination has highest efficacy in diagnosing appendicitis in comparison when Gray scale US and Alvarado score are used alone. Thus, ultrasound should be the first investigation of choice in patients with clinically suspected appendicitis. Color Doppler should be used in combination with Gray scale ultrasonography to improve diagnostic efficacy.

Acknowledgement

It has been always a great honor and privilege to work as a Resident at Mahatma Gandhi Institute of Medical Sciences. The enthusiastic atmosphere and rich discussions among my colleagues definitely helped me construct my knowledge to a new level.

I am thankful to Dr. A.T. Tayde, Professor and Head and also Dr. S.K. Kale, Professor of the Department of Radiodiagnosis whose invaluable guidance helped me develop an interest in my work and

understand it in a better way. I would also like to thank Dr. A.T. Tayade for providing me guidance and with all the essential facilities and support to successfully complete my work.

REFERENCES

1. Williams NS, Bulstrode JKC, Connell PRO, editor; Bailey & Love's Short Practice of Surgery. 25th ed, Hodder Arnold, UK, 2008:1205-6.
2. Gamanagatti S, Vashisht S, Kapoor A, Chumber S, Bal S; Comparison of graded compression ultrasonography and unenhanced spiral computed tomography in the diagnosis of acute appendicitis. Singapore Med J, 2007;48(1):80-7.
3. Summa M, Perrone F, Priora F, Testa S, Quarati R, Spinoglio G; Integrated clinical-ultrasonographic diagnosis in acute appendicitis. J Ultrasound, 2007;10(4):175-8.
4. Wan MJ, Krahn M, Ungar WJ, Caku E, Sung L, Medina LS, *et al.*; Acute appendicitis in young children: cost-effectiveness of US versus CT in diagnosis--a Markov decision analytic model. Radiology, 2009;250(2):378-86.
5. Kurane SB, Sangolli MS, Gogate AS; A one year prospective study to compare and evaluate diagnostic accuracy of modified Alvarado score

- and ultrasonography in acute appendicitis in adults. *Indian J Surg*, 2008;70(3):125-9.
6. Quillin SP, Siegel MJ; Color Doppler US of children with acute lower abdominal pain. *Radiographics*, 1993;13(6):1281-93.
 7. Kaiser S, Frenckner B, Jorulf HK; Suspected appendicitis in children: US and CT--a prospective randomized study. *Radiology*, 2002;223(3):633-8.
 8. Beasley SW; Can we improve diagnosis of acute appendicitis? *BMJ*, 2000; 321(7266):907-8.
 9. Hernanz-Schulman M; CT and US in the diagnosis of appendicitis: an argument for CT. *Radiology*, 2010;255(1):3-7.
 10. Sharma R, Kasliwal DK, Sharma RG; Evaluation of negative appendectomy rate in cases of suspected acute appendicitis and to study the usefulness of ultrasonography in improving the diagnostic accuracy. *Indian J Surg*, 2007;69(5):194-7.
 11. Pinto F, Pinto A, Russo A, Coppolino F, Bracale R, Fonio P, *et al.*; Accuracy of ultrasonography in the diagnosis of acute appendicitis in adult patients: review of the literature. *Crit Ultrasound J*, 2013;5 Suppl 1:S2.
 12. Puylaert JB; Acute appendicitis: US evaluation using graded compression. *Radiology*, 1986 Feb;158(2):355-60.
 13. Douglas CD, Macpherson NE, Davidson PM, Gani JS; Randomised controlled trial of ultrasonography in diagnosis of acute appendicitis, incorporating the Alvarado score. *BMJ*, 2000;321(7266):919-22.
 14. Birnbaum BA, Wilson SR; Appendicitis at the millennium. *Radiology*, 2000;215(2):337-48.
 15. Lim JH; Ultrasound examination of gastrointestinal tract diseases. *J Korean Med Sci*, 2000;15(4):371-9.
 16. Styruud J, Josephson T, Eriksson S; Reducing negative appendectomy: evaluation of ultrasonography and computer tomography in acute appendicitis. *Int J Qual Health Care*, 2000;12(1):65-8.
 17. Babcock DS; Sonography of the acute abdomen in the pediatric patient. *J Ultrasound Med*, 2002;21(8):887-99; quiz 900-1.
 18. Mardan MA, Mufti TS, Khattak IU, Chilkunda N, Alshayeb AA, Mohammad AM, *et al.*; Role of ultrasound in acute appendicitis. *J Ayub Med Coll Abbottabad*, 2007;19(3):72-9.
 19. Gaitini D, Beck-Razi N, Mor-Yosef D, Fischer D, Ben Itzhak O, Krausz MM, *et al.*; Diagnosing acute appendicitis in adults: accuracy of color Doppler sonography and MDCT compared with surgery and clinical follow-up. *AJR Am J Roentgenol*, 2008;190(5):1300-6.
 20. Lim HK, Lee WJ, Kim TH, Namgung S, Lee SJ, Lim JH; Appendicitis: usefulness of color Doppler US. *Radiology*, 1996;201(1):221-5.
 21. Addiss DG, Shaffer N, Fowler BS, Tauxe RV; The epidemiology of appendicitis and appendectomy in the United States. *Am J Epidemiol*, 1990;132(5):910-25.
 22. Sidhu PS CW; Measurement in ultrasound a practical handbook. 1st ed, editor: Arnold, London, 2004.
 23. Yacoe ME, Jeffrey RB; Jr. Sonography of appendicitis and diverticulitis. *Radiol Clin North Am*, 1994 ;32(5):899-912.
 24. Keyzer C, Zalcman M, De Maertelaer V, Coppens E, Bali MA, Gevenois PA, *et al.*; Comparison of US and unenhanced multi-detector row CT in patients suspected of having acute appendicitis. *Radiology*, 2005 Aug;236(2):527-34.
 25. Scammell S, Lansdale N, Sprigg A, Campbell D, Marven S; Ultrasonography aids decision-making in children with abdominal pain. *Ann R Coll Surg Engl*, 2011;93(5):405-9.
 26. Van Randen A, Lameris W, van Es HW, ten Hove W, Bouma WH, van Leeuwen MS, *et al.*; Profiles of US and CT imaging features with a high probability of appendicitis. *Eur Radiol*, 2010;20(7):1657-66.